

# A modified direct lateral approach in total hip arthroplasty

V.S.Pai

Healthcare Hawkes Bay, Hastings, New Zealand

---

## ABSTRACT

A modified lateral approach of Hardinge allows adequate access for orientation of the implant was described. Although this approach is more difficult than the posterior approach, there is a learning curve, when mastered, it'll definitely reduce the incidence of dislocation. In the Author's opinion, this approach should be used routinely for total hip arthroplasty for fractured neck of femur where the incidence of dislocation is unacceptably high using the posterior approach.

*Key words:* total hip arthroplasty, fracture neck of femur, lateral approach of the hip

---

## INTRODUCTION

A direct lateral approach to the hip joint was first described by McFarland and Osborne (1954)<sup>10</sup> based on the basic anatomical principle that the gluteus medius and vastus lateralis muscles act in functional continuity via their fascial connection over the greater trochanter. He detached the whole gluteus medius together with the vastus lateralis from the posterior

border of the greater trochanter and swung them forward like a bucket handle. This lateral approach was popularized by Hardinge (1982)<sup>6</sup> by reflecting the anterior half of the gluteus medius and vastus lateralis. Since then many modifications (Table 1) have been reported.<sup>2,4,9,11</sup>

Good results can be achieved in the majority of cases irrespective of the type of approach. However, post-operative dislocation is still a problem, more so when performed for fractured neck of femur. The incidence of dislocation is much less in the lateral approach compared to other approaches.<sup>8,13,14</sup>

Discouraged by an unacceptably high dislocation rate using the posterior approach, I turned to a direct lateral approach for total hip arthroplasty in 1991. After a period on the learning curve, incorporating some modifications, a standardized modified approach as described here has been used prospectively in 40 patients for total hip replacement for fracture neck of femur. No dislocation has occurred in these cases.

## SURGICAL TECHNIQUE

The patient was placed in the full lateral position on the operating table. A straight lateral skin incision was made midway between the anterior and posterior border of the greater trochanter centering on the tip of the trochanter.

The fat and fascia lata are incised in line with the

**Table 1**  
**Various modification of McFarland and Osborne lateral approach to the hip**

	Hardinge <sup>6</sup>	Learmonth <sup>8</sup>	Mulliken <sup>13</sup>	Dall <sup>2</sup>	McLauchan <sup>11</sup>	Pai
<sup>1</sup> G-V flap	1/2	Complete	1/3	1/2	1/2	1/3
<sup>2</sup> Proximal Extension from trochanter	NS		3 cm	2 cm	NS	3 cm
<sup>3</sup> Anterior Osteotomy	-	-	-	+	+	-
<sup>4</sup> Capsule	R/E	E	E	R/E	R/E	R
<sup>5</sup> G-V flap Repair	T-T	T-B	T-T	B-B	B-B	T-B

<sup>1</sup> G-V flap(Gluteus-vastus): Width of the anterior flap in relation to width of the muscle

<sup>2</sup> Proximal extension of the glutei split from the tip of the greater trochanter:(NS = Not specified)

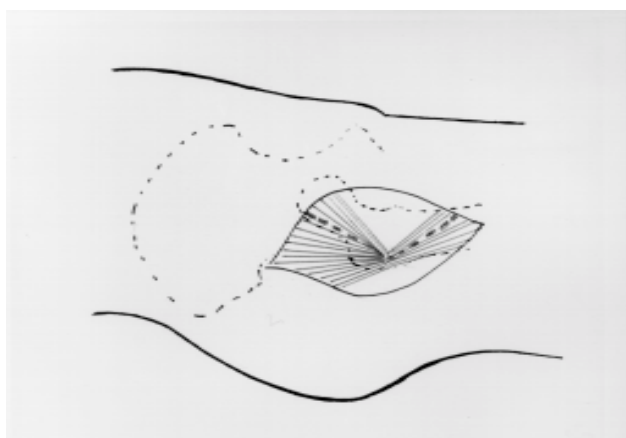
<sup>3</sup> Anterior Osteotomy: Flap is elevated with a piece of trochanter

<sup>4</sup> Capsule R/E = Retained or Excised

<sup>5</sup> G-V flap repair: T-T = Tendon to tendon repair; T-B = Tendon (flap) to the bone with bone stitches; B-B = Bone to bone following trochanteric osteotomy

skin incision and retracted with a self-retaining retractor. At the proximal part of the fascia lata, gluteus maxius insertion to the fascia lata is encountered, which is split in line with the fascia lata. The trochanteric bursa was incised to demonstrate the anterior and posterior borders of the gluteus medius and the vastus lateralis.

Blunt dissection was used to split the anterior third of the gluteus medius. Usually a layer of fat is visible deep to gluteus medius. This split is in the direction of the muscle fibres, which makes anterior 45° angulation to the skin incision (Fig. 1). The split was not extended more than 3 cm cephalad to the insertion of the trochanter to protect the inferior branch of the superior gluteal nerve.



**Figure 1** Abductor split in the anterior one-third of the gluteus medius

Next, distal blunt dissection was carried out through the anterior part of the vastus lateralis passing down to the bone for about 3 cm. The lateral part of the origin of vastus medialis was observed deep to vastus lateralis from the intertrochanteric line. These fibres are divided. The ascending branch of the medial circumflex artery and the transverse branch of the lateral circumflex artery in the vastus lateralis are encountered and can be easily cauterized.

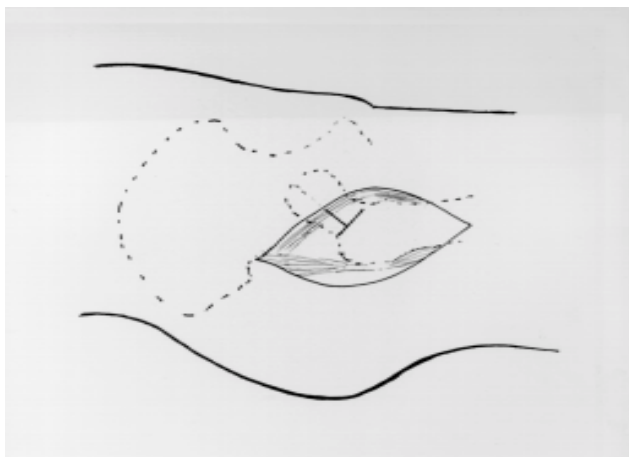
The now split portion of gluteus medius is connected to that of vastus lateralis over the greater trochanter at the junction of anterior third with posterior 2/3 as shown in the (Fig. 1) using electrocautery.

With sharp dissection, elevate a flap consisting of the anterior part of the gluteus medius muscle with its underlying gluteus minimus and the anterior part of the vastus lateralis muscle.

There is a surgical plane between the glutei and capsule marked by areolar tissue, and dissection was carried out in this plane to the acetabular rim. The flap was retracted with a self-retaining retractor and the patient's leg is externally rotated to visualize the full length of the capsule with its overlying iliofemoral ligament.

A 'T' shaped incision was made on the anterior capsule with the vertical limb of the 'T' along the intertrochanteric line and the horizontal limb across the anterior surface of the capsule to the acetabular rim (Fig. 2).

At this stage, the head of the femur was dislocated by flexion, adduction and external rotation. The leg



**Figure 2** T shaped incision is made in the hip capsule before anterior dislocation by flexion, adduction and external rotation

was brought over into sterile pouch to perform a femoral neck osteotomy. In osteoporotic bone, care should be taken during this maneuver and no force should be used to dislocate the hip. In difficult circumstances, a corkscrew is used to deliver the head or neck is ostetotomised and the head is removed with the cork screw.

The capsule was retained and retracted using two Steinman pins, one placed at 11 o'clock and the other at 2 o'clock position on the outer aspect of the limbus. Sometimes the approach may not be adequate and an additional capsulotomy is needed. This is performed at the 5 o'clock position, taking extreme care not to damage the sciatic nerve.

For acetabular preparation, a Hohmann retractor was placed in the acetabular notch beneath the transverse acetabular ligament. Rarely is a posterior rim retractor required.

The limbus was excised throughout the circumference of the acetabulum. The transverse acetabular ligament was divided and excised. The acetabulum was prepared in the usual fashion.

For femoral preparation, the leg was held perpendicular to the floor. Care has to be taken while preparing the femoral shaft as it is not uncommon to damage the posterior fibres of the gluteus medius with the rasp. This can be avoided by retracting this muscle with a blunt Hohmann retractor.

It is not necessary to excessively antevert or retrovert the acetabular or femoral components through this approach. In fact, it is generally acceptable to recreate the desired normal anatomy; that is, approximately 15° of acetabular anteversion and 5 – 10° of femoral anteversion. When proper soft tissue tension is achieved, stability of the joint can be

demonstrated on flexion, adduction and internal rotation.

Careful attention to the detail of closure of the muscular layers is important to the success of this approach. A 1 Vicryl was used to repair the horizontal limb of the capsule. The vertical limb of the capsule was not repaired. The conjoint tendon flap (gluteus medius and minimus, vastus lateralis) was repaired to the greater trochanter with bone stitches using 5 Ethibond. The split gluteus and vastus are approximated with light 1 Vicryl stitches. The fascia lata, subcutaneous tissues and skin are closed in the usual fashion.

Postoperative rehabilitation following total hip arthroplasty has been carried out as follows: A pillow was placed between the patient's legs until they are awake in the recovery room. A knee brace was used for the first 24 hours and ambulation with assistance begun the next day. For the first 6 weeks, patients begun with crutch walking, progressing to full weight bearing as tolerated. Patients generally are released from physiotherapy and the use of a cane at 3 months was allowed to progress to full activity.

## DISCUSSION

Total hip replacement is one of the most successful and rewarding operations ever developed. This surgery has undergone considerable evolution during the past 40 years; not only have a large number of prosthesis designs been developed but a large number of surgical techniques and approaches have been described.

Despite these advances in total hip arthroplasty, dislocation remains a frequent complication and has been reported to be 3–5% for primary osteoarthritis. This incidence can increase up to 18% for total hip replacement used for fractured neck of femur.<sup>17</sup> Dislocation can occur even after good orientation of the components and proper tissue tension. Dislocations are still seen after the posterior approach, even in the hands of an experienced surgeon.<sup>18</sup>

The cause for the increased incidence of prosthetic dislocation in fractured neck of femur is multifactorial: Poor prosthetic alignment is still a common cause for dislocation irrespective of type of approach. It has been reported that the movement in the replaced hip for a fractured neck of femur is greater than that for osteoarthritis and this may be a factor for increased incidence of dislocation.<sup>5</sup> Confusion, mental competence and balance problems may also contribute to the higher incidence of dislocation.

Taking these factors into consideration, it is important to adapt to an approach which gives

consistently better results. There are prospective reports on direct lateral approaches and its modification, which give consistently a stable hip.<sup>8,13</sup> My modified approach has been used prospectively in 40 patients with fractured neck of femur and early results are encouraging. There were no dislocations, even though two patients had further falls and sustained a fracture of the tibia.

The reported modified approach differs from Hardinge approach in several ways:

1. By splitting gluteus medius in 1/3 of its anterior, a large portion of the posterior 2/3 of the gluteus medius remains undisturbed at its point of insertion on the greater trochanter.
2. The superior extension of the abductor split is only 3 cm, maintaining a safe distance from the inferior branch of superior gluteal nerve<sup>1</sup>.
3. A "T" shaped incision was made on the anterior capsule with the vertical limb of the T along the intertrochanteric line and the horizontal limb across the anterior surface of the capsule to the acetabular rim. The capsule is retained and retracted using Steinman pins.
4. With the posterior capsule intact and the anterior capsule repaired, this modification gives soft tissue protection against dislocation.
5. The gluteus-vastus flap was repaired to the bone with 5 ethibond to prevent avulsion of the flap from the bone.
6. Finally the patient is placed in the lateral decubitus position (cf. supine in Hardinge approach) which would allow direct visualization of the relevant anatomy.

There is always reluctance among surgeons to change the surgical approach from what they are used to. But for those used to the posterior approach, adapting to the direct approach should not be a problem as both approaches are carried out in the lateral position.

In this modified approach, most of the gluteus medius was left intact. Technically it is possible to damage the inferior branch of superior gluteal nerve. The postoperative strength of the abductors of the operated side was the same as that on the non-operated side and functionally, the direct lateral approach was a safe alternative to other approaches.<sup>3,4,6,11,14</sup> Svenson<sup>16</sup> studied the postoperative integrity of the conjoined aponeurosis of the gluteus medius and vastus lateralis in the Hardinge approach using metal markers. He suggested that the gluteal limp is due to dehiscence of the flap, then damage to the superior gluteal nerve. This problem may be minimized by stitching the flap to the bone as suggested in my approach (Table 1).

The modified direct lateral as described in this study offers predictable and easy access to the hip joint and provides excellent exposure of both acetabular and proximal femoral regions. Dislocation occurs infrequently, and postoperative limp is not a major problem (Table 2). In this modified approach, the posterior capsule intact and the anterior capsule repaired, provides a soft tissue envelope around the joint. This may give additional stability against dislocation.

Table 2  
Outcome of total hip replacement for fracture  
neck of femur

Ref	Number (Patients)	Mortality 1 yr (%)	Dislocation (%)	Results (%)
Pai	35	3	0	86
Coates	85	7 (1 month)	18	87
Delamarter	27	14	0	87
Gebhard	44	NA	2	86
Greenough	35	0	8	49
Gregory	46	2	9	64
Lee	126	6	10	86
Pun	46	0	8	94
Sim	85	NA	14	89
Skinner	90	23	13	80
Taine	163	10 (6 months)	12	62

## ACKNOWLEDGEMENTS

The author is grateful to Dr Peter Lloyd for his help in preparing this manuscript and to Mr Wayne Blair, medical photographer, Healthcare Hawkes Bay.

(No benefits in any form have been received or will be received from any commercial party related directly or indirectly to the subject of this article.)

## REFERENCES

1. **Comstock C, Imrie S, Goodman SB.** A clinical and radiographic study of the 'safe area' using the direct lateral approach for total hip arthroplasty. *J Arthroplasty* 1994; 9(5): 527-31.
2. **Dall D.** Exposure of the hip by anterior osteotomy of the greater trochanter. *J Bone Joint Surg* 1986; 68B: 382-5.
3. **Downing ND, Clark DI, Hutchinson JW, Colclough K, Howard PW.** Hip abductor strength following total hip arthroplasty: a prospective comparison of the posterior and lateral approach in 100 patients. *Acta Orthop Scand* 2001; 72(3): 215-20
4. **Frndak PA, Mallory TH, Lombardi AV Jr.** Translateral surgical approach to the hip: the abductor split. *Clin Orthop* 1993; 295: 135-40.
5. **Gregory RJH, Gibson MJ, Moran CG.** Dislocation after primary arthroplasty for subcapital fracture of the hip. *J Bone Joint Surg* 73(B): 11-2.
6. **Hardinge K.** The direct lateral approach to the hip. *J Bone Joint Surg* 1982; 64 B: 17-8.
7. **Hardy AE.** Synek V: Hip abductor function after the Hardinge approach: brief report. *J Bone Joint Surg (Br)* 1988; 70(B): 673.
8. **Hungerford DS.** Surgical approach in THA: the direct lateral approach is more practical and appealing. *J Arthroplasty* 2000;15 (7): 867-70.
9. **Learmonth ID, Allen PE.** The omega lateral approach to the hip. *J Bone Joint Surg* 1996; 78(B): 559-61.
10. **McFarland B, Osborne G.** Approach to the hip: a suggested improvement on Kocher's method. *J Bone Joint Surg* 1954; 36 (B): 364-7.
11. **Mclauchan J.** The Stracathro Approach to the hip. *J Bone Joint Surg* 1984; 66B:30-3.
12. **Minns RJ, Crawford RJ, Porter ML, Hardinge K.** Muscle strength following total hip arthroplasty. A comparison of trochanteric osteotomy and the direct lateral approach. *J Arthroplasty* 1993; 8(6): 625-7.
13. **Mulliken BD, Rorabeck CH, Bourne RB, Nayak N.** A modified direct lateral approach in total hip arthroplasty. *J Arthroplasty* 1998;13(7): 737-47.
14. **Pai. VS.** Early recurrent dislocation in total hip arthroplasty. *J Orthopaed Surg* 1995; 3(2): 65-71.
15. **Pai. VS.** Significance of the trendlenburg test in total hip arthroplasty. *J Arthroplasty* 1996; 11(2): 174-9.
16. **Svenson O.** Integrity of the gluteus medius after the transgluteal approach in THR. *J Arthroplasty* 1990; 5(1): 57-62.
17. **Taine WH, Armour PC.** Primary total hip replacement of displaced subcapital fractures of the femur. *J Bone Joint Surg (Br)* 1985; 67B: 214-7.
18. **Woo RYG, Morrey BF.** Dislocation after total hip arthroplasty. *J Bone Joint Surg (Am)* 1982; 64: 1295-302.