

Osteophyte at the sacroiliac joint as a cause of sciatica: A report of four cases

Bhaskaranand Kumar, K.G. Sriram, Chacko George
Kasturba Medical College, Manipal, Karnataka, India

ABSTRACT

Four cases of sciatica due to osteophytes impinging on the sciatic nerve at the sacroiliac joint are reported. Of these 4 cases, 2 were treated conservatively and the other 2 required surgical excision of the osteophyte. The report highlights the importance of keeping this uncommon etiology in the differential diagnosis of sciatica.

Key Words: sciatica, extraspinal, osteophyte

INTRODUCTION

Sciatica is a common and often disabling symptom of varied etiology. Lumbar disc prolapse is responsible for a majority of cases presenting with sciatica. This fact often overshadows any other lesion causing mechanical nerve root compression that may be closely related to the pathogenesis of sciatica. Thus on most occasions, sciatica gets attributed to intraspinal pathologies to the exclusion of extraspinal pathologies. We are reporting 4 cases of sciatica caused by impingement of the sciatic nerve at the sacroiliac joint by osteophytes. To the best of our knowledge, only one such case has been reported.²

CASE REPORTS

Case 1

A 41-year-old housewife presented with low back pain radiating to the right lower limb of 1 year duration. The pain was insidious in onset, progressive and pricking type. It was unaffected by coughing and sneezing and unrelieved by rest. Examination of the spine showed obliteration of lumbar lordosis and presence of paraspinal muscle spasm. There was no spinal tenderness. On the right side, straight leg raising was restricted to 50° with Grade 3 power in the extensors of the toe and sensory blunting in L₅ dermatome.

Radiographs of the lumbar spine and pelvis showed early spondylotic changes. The patient was treated conservatively for intervertebral disc prolapse but showed no signs of improvement after 2 weeks. A myelogram was then performed, which was normal. This led us to explore the possibility of an alternative diagnosis. On further clinical examination tenderness was elicited at the right sciatic notch. A critical examination of the radiograph revealed a large osteophyte at the inferior margin of the right sacroiliac joint.

A local injection of 1 ml of 1% xylocaine at the site of maximum tenderness was given. The patient was relieved of her symptoms immediately. However, the pain recurred with the same intensity after 2 weeks. A decision was then taken to surgically excise the

osteophyte. The sciatic nerve was exposed through the Moore's approach. Intraoperatively a swollen and congested sciatic nerve was being impinged by a large osteophyte at the inferior border of right sacroiliac joint. Excision of the osteophyte relieved the patient of her symptoms and she was asymptomatic for the last eight years.

Case 2

A 52-year-old housewife was referred to us for evaluation of pain in the right buttock and lower extremity of 2 years duration. The pain worsened on standing for long hours and was unrelieved by rest. On examination, there was no evidence of paraspinal muscle spasm. There was tenderness at the level of the right sciatic notch. Neurological examination was normal. There was a positive straight leg-raising test at 40° on the right side. Radiographs of the lumbar spine and pelvis revealed a large osteophyte at the inferior border of the right sacroiliac joint. She was relieved of her symptoms with a local injection of 1 ml of 1% xylocaine and 2ml of 1% dexamethasone at the site of maximum tenderness. Patient is now asymptomatic for the last three years.

Case 3

A 47-year-old bank employee was referred to us for persistent pain in the left lower buttock and thigh of 3 years duration. He had mild parasthesia in the left posterior thigh and gluteal fold. A physician treated him by means of bed rest, traction and analgesics, but to no avail. Examination revealed tenderness on palpation in the left sciatic notch. Neurological examination was normal, deep tendon reflexes were Grade 2 on the left side. Straight leg-raising on the left at 50° caused pain in the left gluteal region and upper posterior thigh. Radiographs of the lumbar spine and pelvis revealed an osteophyte at the inferior border of left sacroiliac joint. A local injection of xylocaine with a steroid at the site of maximum tenderness was given which relieved the patient of his symptoms immediately. The patient has been in our follow up for the last two years without any recurrence of symptoms.

Case 4

A 53-year-old teacher came to us with a one year history of right sided sciatic pain radiating to the posterolateral aspect of the leg and foot. She had been treated conservatively for lumbar disc herniation without any improvement.

There was no paraspinal muscle spasm or tenderness in the lumbar spine. Palpation elicited point tenderness at the right sciatic notch and reproduced the pain in the leg and foot. Straight leg-raising was limited to 40° and the Achilles reflex was absent on the right side. In addition, the patient had diminished sensation in the region of S₁ dermatome on the right side. Radiographs revealed an osteophyte at the inferior margin of right sacroiliac joint. She was given local injection of xylocaine with a steroid which relieved her of symptoms immediately but the pain recurred with the same intensity within one week. Surgical excision of the osteophyte relieved the patient of her symptoms completely and she continues to be asymptomatic for the last year.

DISCUSSION

Sciatica affects up to 40% of adults and may be caused by various intraspinal or extraspinal pathologies. Most of these cases get attributed to lumbar intervertebral disc prolapse ignoring the fact that 20% of normal or asymptomatic patients show a prolapsed disc on CT or MRI. Sciatica may often be engendered by the less common intraspinal pathologies, which can be diagnosed during routine imaging for disc prolapse.³

Extraspinal pathologies causing sciatica are infrequent. On most occasions these are not only ignored but because of their location, may not be imaged on routine assessment. Failure to identify these extraspinal pathologies leads to wrong diagnosis and inappropriate management and consequently poor results.

Documented extraspinal causes of sciatica include tumours, aneurysms of iliac³ or gluteal arteries,⁸ anorectal abscess, avulsion fracture of ischial tuberosity,⁷ endometrioma in the pelvic cavity^{5,11}, and piriformis muscle syndrome⁹. Rare iatrogenic causes of sciatica reported are entrapment of sciatic nerve following tension band wiring of osteotomized trochanter after a total hip arthroplasty⁶ or migration of these wires which broke at a later date.¹ There has also been a report of impingement of intrauterine device on sciatic nerve after uterine perforation.⁴

Osteophytosis at the sacroiliac joint has been studied in cadavers but its clinical implications have not been elucidated. When present unilaterally, there was a mild predilection to the right side. These are more common in males than females. The male and female sacroiliac joints are diverse in their function. The male joints being built for strength, the osteophytes are situated in the superior part of the sacroiliac joint, which is in the line of weight transmission from axial

skeleton to lower limb. The female joints are more mobile to facilitate parturition. In females, the stress produced by this mobility is concentrated at the inferior aspect of the sacroiliac joint which explains the presence of osteophytes in this region.¹⁰ Osteophytes at the anteroinferior portion of the joint when large can cause sciatic nerve root compression (Fig. 1)

Patients who present with sciatica with imaging studies showing presence of an osteophyte at the sacroiliac joint (Fig. 2). The possibility of this osteophyte pressing on the sciatic nerve should be considered. This can be confirmed by eliciting tenderness at the said region and local injection of steroids and xylocaine that will dramatically reduce the pain. If the symptoms recur then surgical excision of the osteophyte should be done (Fig. 3).

The present report highlights the need to identify such unusual causes of sciatica when it cannot be attributed to its common causes.

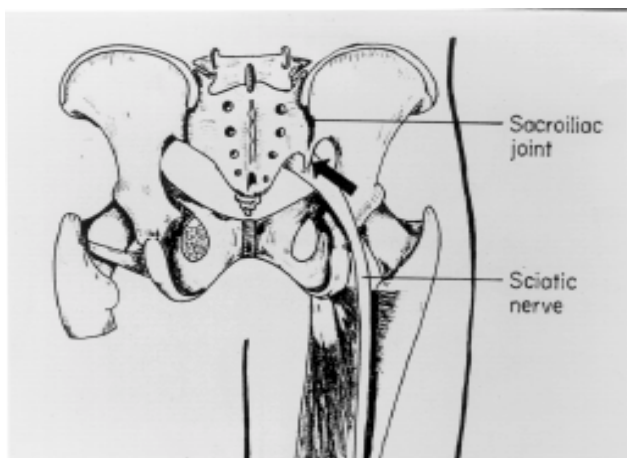
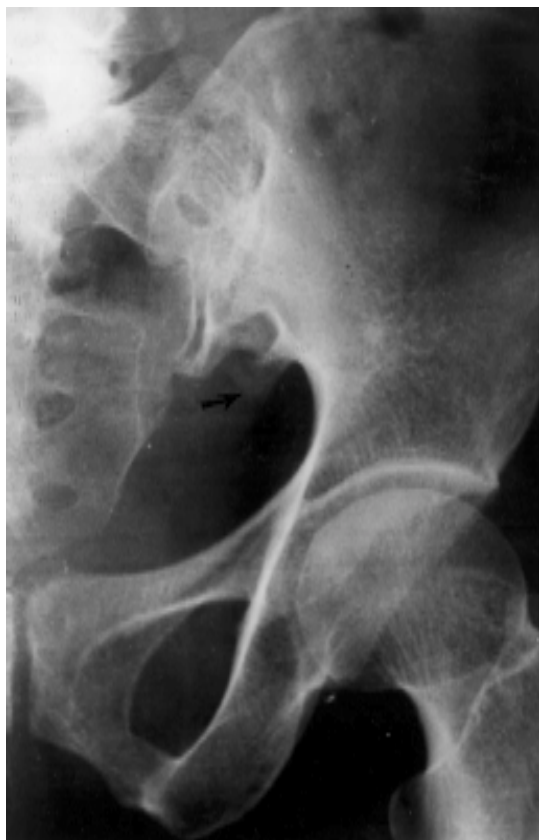

Figure 1 Pelvis viewed posteriorly. Solid black arrow indicates the osteophyte impinging on the Sciatic nerve.



◀ **Figure 2** Anteroposterior radiograph of the sacroiliac joint showing the osteophyte at its inferior margin.



Figure 3 Intraoperative view showing the osteophyte (held by forceps) that was impinging on the sciatic nerve.

REFERENCES

1. **Asnis SE, Hanley S, Shelton PD.** Sciatic neuropathy secondary to migration of trochanteric wire following Total Hip Arthroplasty. *Clin. orthop.* 1985; 196: 226–8.
2. **Chaabane M, Abid R, Hamza K, Aloulou R, Robbana A, Chaabouni L, Hamza R.** Uncommon etiology of cruralgia. *J. Radiol* 1994; 75(5): 283–5.
3. **Dudeney S, O' Farrel D, Hayes DB, Byrne J.** Extraspinal causes of sciatica. A case report. *Spine* 1998; 23 (4): 494–6.
4. **Elmer RM.** Sciatica caused by an intrauterine device after silent uterine perforation. *J Bone Joint Surg* 1978; 60-A: 265–7.
5. **Head HB, Welch JS, Mussey E, Espionasa RE.** Cyclic sciatica, report of case with introduction of new surgical sign. *JAMA* 1962; 180: 521–4.
6. **Mallory TH.** Sciatic nerve entrapment secondary to trochanteric wiring following Total Hip Arthroplasty. A case report. *Clin. Orthop.* 1983; 180: 198–200.
7. **Miller A, Stedman GH, Beisaw NE, Gross PT.** Sciatica caused by avulsion fracture of the ischial tuberosity. *J Bone Joint Surg* 1987; 69-A: 143–5.
8. **Papadopoulos SM, McGillicuddy JE, Messina LM.** Pseudoaneurysm of inferior gluteal artery presenting as sciatic nerve compression. *Neurosurgery* 1989; 24: 143–5.
9. **Solheim LF, Siewers P, Paus B.** The piriformis muscle syndrome.. *Acta Orthop Scand* 1981; 52: 73–5.
10. **Stewart TD.** Pathological changes in aging sacroiliac joints. *Clin. Orthop* 1984; 183: 188–96.
11. **Takata K, Takahashi K.** Cyclic sciatica. *Spine* 1994; 19: 89–90.