

Chondrosarcoma of the thoracic spine in an 8-year-old child with 12 years follow-up: A case report

Nick Vertzyas, John Cummine, Sandra Biankin and Michael Bilows

Division of Orthopaedic Surgery and Department of Tissue Pathology, Westmead Hospital, Sydney, Australia.

INTRODUCTION

Chondrosarcoma of the spine is very rare. One case of chondrosarcoma involving the head of the left 8th rib, treated by total removal of the tumour and postoperative radiotherapy in an 8-year-old girl is discussed. The patient was followed up for 12 years in our Outpatient Clinic with no evidence of tumour recurrence. A lower thoracic scoliosis developed.

Key words: *chondrosarcoma, radiotherapy, spine, scoliosis, child*

CASE REPORT

An 8½-year-old girl presented with a one-month history of a lump on the left thoracic area, just off the midline. The girl was otherwise well. Her history was uneventful and her development had been normal. She had no serious illnesses. Examination revealed a soft, diffuse, non-tender swelling 3 x 3 cm over the upper

thoracic vertebrae to the left of the midline, just below the scapulae. It did not extend under the scapula and did not appear to be fixed to the fatty tissue, bone or muscle. No skin discolouration or any other suggestion of a venous component was noted. There was no axillary lymphadenopathy. The abdomen, liver and spleen were normal. The chest X-ray was clear. The provisional diagnosis of fibrolipoma was made. Ultrasound reported a complex fibro fatty swelling.

Thoracic spine CT (Figs. 1 & 2)

At T8, on the left, a paraspinal soft tissue mass extended into the IV foramen below, but did not encroach upon the contents of the spinal canal. Destruction of the head and neck of the left 8th rib was evident with some soft tissue calcification and an abnormal trabecular pattern in the transverse process of T9. The findings were compatible with a chondrosarcoma.

A biopsy of the lesion was described as a lobular, firm to hard opalescent mass between the spinous and transverse processes extending into the region of the spinal foramen. The tumour was adherent to the transverse processes.

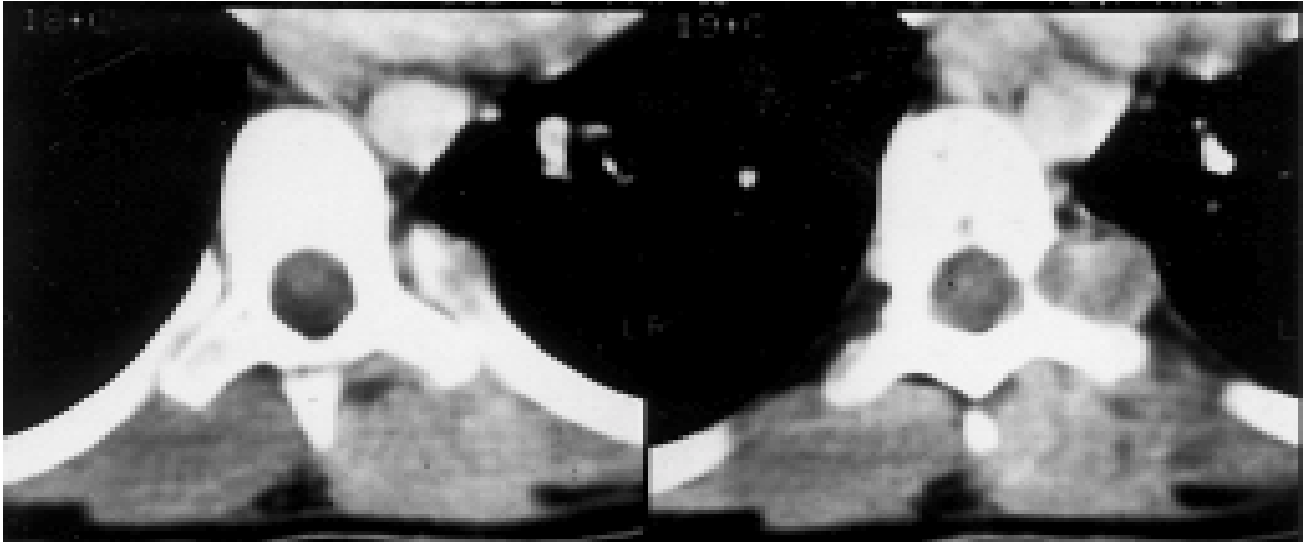


Figure 1 CT scan at the level of T8: The paraspinous soft tissue extended into the intervertebral foramen below, but did not encroach upon the contents of the spinal canal.

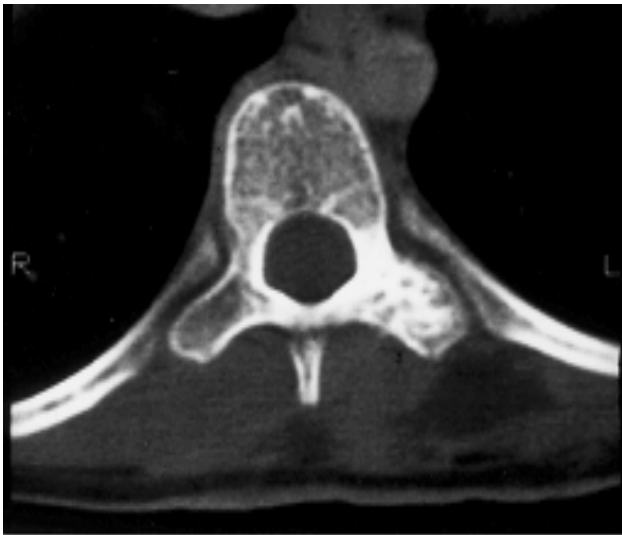


Figure 2 CT scan at the level of T9: The destruction of the head and neck of the left 8th rib and abnormal trabecular pattern in the transverse process of T9.

Histopathology of the biopsy specimen

The appearances were those of chondrosarcoma Grade II. A transthoracic resection was performed.

Histopathology of the resected specimen (Figs. 3 & 4)

All specimens showed Grade I chondrosarcoma. The tumour involved the transverse process infiltrating the

surrounding skeletal muscle and fibrovascular tissue. The specimen was sent to Dr K Unni at the Mayo Clinic for further review and he concurred with the diagnosis of Grade I chondrosarcoma. Postoperatively the patient was referred to Professor Langlands in the Radiation Oncology Department. He suggested that there could be no certainty that excision was radical in this area and recommended radiotherapy. She was treated with 6 Mev radiotherapy to the lower thoracic spine, dose 45 Gy, in 25 fractions and 40 days. The spinal cord dose accepted was 45.7 Gy. She has been followed up as an outpatient for 12 years, and by all criteria she is tumour free. She developed progressive scoliosis, which required brace treatment.

DISCUSSION

Chondrosarcoma of the spine is rare, but it is the second most common primary malignant tumour of bone.³ Chondrosarcoma represents 7.6% of primary malignant bone tumours.⁵ Törmä described 250 histologically verified malignant tumours of the spine and spinal extradural space. He described 11 cases of chondrosarcoma.¹³

Chondrosarcomas of the spinal column are most frequently found in the thoracic spine.^{4,13} Six to 10% of all chondrosarcomas occur in the spinal column.¹⁰ Chondrosarcomas of the spine have a higher incidence in patients less than 21 years of age and there is a male preponderance.⁸ Radiographically, chondrosarcomas are osteolytic with a soft tissue expansion with poor

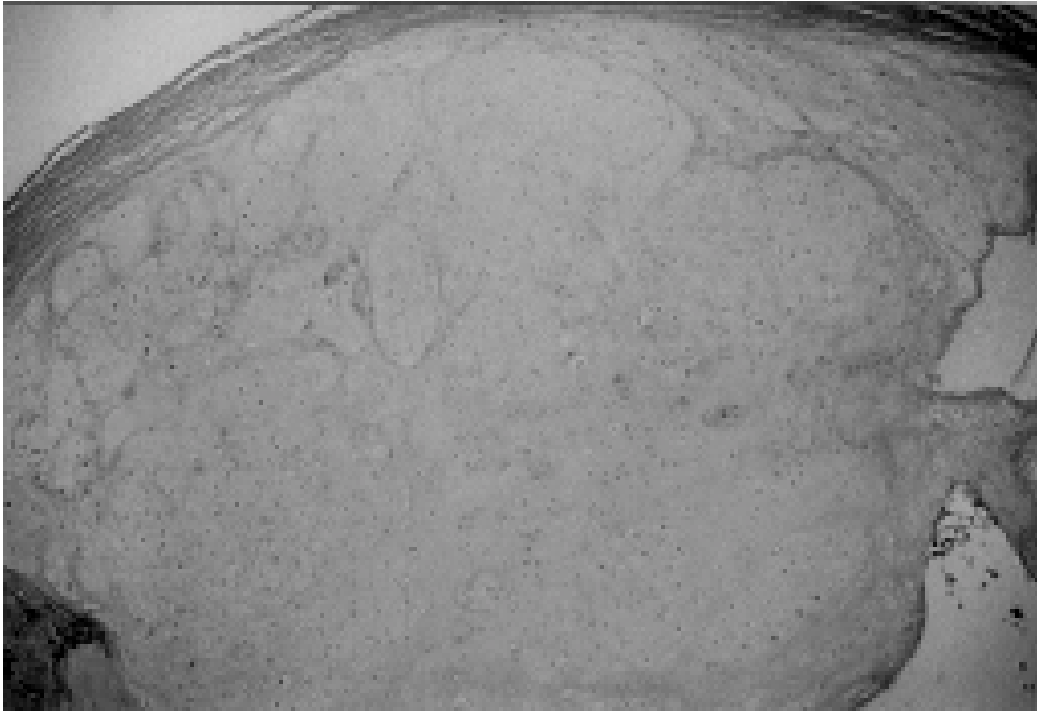


Figure 3 (H&E x 25): Low power view of the tumour showing the loculated architecture.

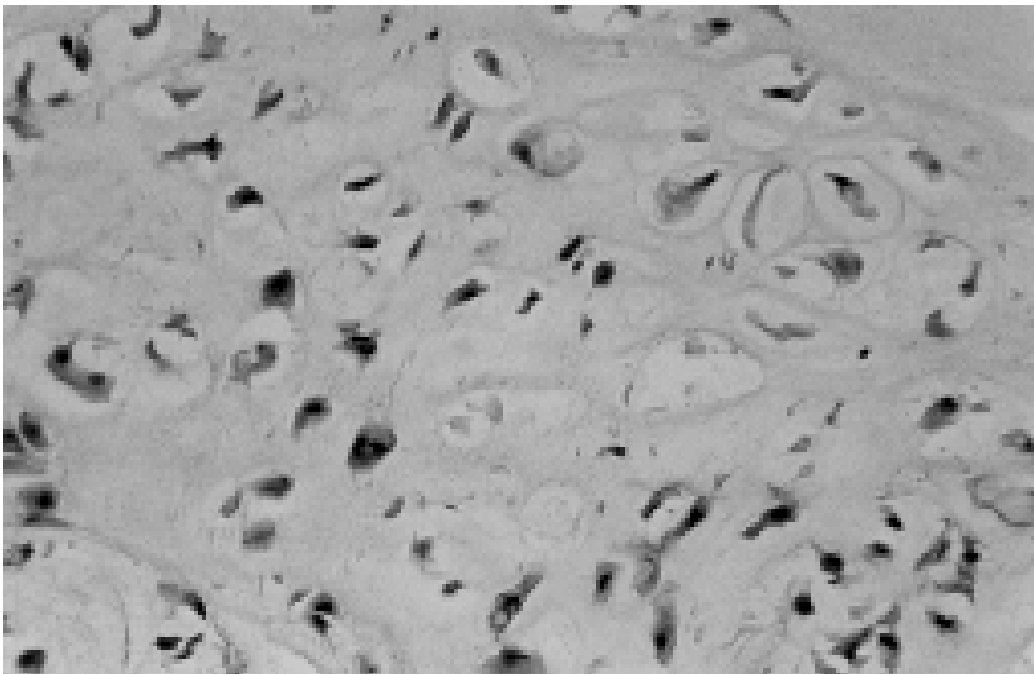


Figure 4 (H&E x 400): These atypical chondrocytes show binucleated forms and mitoses. The appearance is that of Grade I chondrosarcoma.

margins and mottled calcification.¹² Only a mild periosteal reaction may be evident.¹ The treatment of chondrosarcoma is surgical excision.² Surgical cure of spinal chondrosarcoma is uncertain because total excision may be difficult, and local recurrence is well documented. The use of postoperative radiotherapy in the treatment of chondrosarcoma is quite controversial. Chondrosarcomas are not in the group of tumours that are thought to be radiosensitive.¹¹ In a study of 12 patients by Harwood et al., they reported that radiotherapy contributed to local disease control.⁷ They suggested that radiotherapy would be most useful in situations where surgical resection was not possible or where surgical margins were not complete. Chemotherapeutic agents have not proven to be helpful.⁶

Histological subtyping or grading correlates with prognosis. Thompson and Turner-Warwick classified chondrosarcomas into 3 types:¹²

Grade I: This is a low grade, well-differentiated tumour containing increased numbers of cartilaginous cells with well-formed matrices. Approximately 71–83% of patients with this tumour type will survive 10 years after treatment.

Grade II: This is an average grade tumour with less

matrix and increased cellularity. The cells vary in size and shape with nuclear irregularities. Less than 50% of patients with this type were alive at 5 years after treatment, and only one third were alive at 10 years.

Grade III: This represents a high grade tumour with anaplasia, mitosis and only rare islands of cartilage. It is similar to osteosarcoma. Only one out of 10 patients survived 3 years in this group. Osteosarcoma metastasised rarely, occurring in < 10% of patients, metastasising usually via blood to the lungs and occasionally to bone.⁵ Grade III tumours have been found to metastasize in 70% of cases whereas Grade I tumours are unlikely to metastasise.⁷

The patient's recovery in this case was complicated by the development of a classic post-thoracotomy scoliosis during her adolescent growth spurt.⁹ Brace therapy was instituted at the age of 13+0, when the Cobb angle reached 40°. She wore the brace for 12 months. At the conclusion of brace treatment, the curve measured 46°, and was unchanged 6 years later.

REFERENCES

1. Bertoni F, Picci P, Bacchini P, Capanna R, Innao V, Bacci G, Campanacci M. Mesenchymal chondrosarcoma of bone and soft tissues. *Cancer* 1983, 52:533–54.
2. Blaylock RL, Kempe LG. Chondrosarcoma of the cervical spine: A case report. *J Neurosurgery* 1976, 44:500–3.
3. Camins MB, Duncan AW, Smith J, Marcove RC. Chondrosarcoma of the spine. *Spine* 1978, 3:202–9.
4. Cotran RS, Kumar V, Robbins SL. *Pathological basis of disease*. 4th ed. Philadelphia: WB Saunders, 1989, 1340–2.
5. Dahlins DC, Henderson ED. Chondrosarcoma a surgical and pathological problem: Review of 212 cases. *J Bone Joint Surg* 1956, 38-A:1025–58.
6. Evans HL, Ayala AG, Romsdahl MM. Prognostic factors in chondrosarcoma of bone. *Cancer* 1977, 40:818–31.
7. Harwood AR, Krajbich JI, Fornasier VL. Radiotherapy of chondrosarcoma of bone. *Cancer* 1980, 45:2769–77.
8. Huvos AG. Chondrosarcoma in the young: A clinicopathological analysis of 79 patients younger than 21 years of age. *Am J Surg Pathol* 1987 Dec, 11(12):930–42.
9. Kawakami N, Winter RB, Lonstein JE, Denis F. Scoliosis secondary to rib resection. *J Spinal Disorder* 1994, Vol 7, No 6:522–7.
10. Pritchard DJ, Lunre RJ, Taylor WF, Dahlin DC, Medley BE. Chondrosarcoma: A clinicopathological and statistical analysis. *Cancer* 1980, 45:149–57.
11. Suit HD, Goiten M, Munzenrider J, Verhey L, Davis KR, Koehler A, Linggood R, Ojermann RG. Definite radiation therapy for chondrosarcoma and chondrosarcoma of base of skull and cervical spine. *J Neurosurgery* 1982, 56:377–85.
12. Thompson AD, Turner-Warwick RT. Skeletal sarcomata and giant-cell tumour. *J Bone Joint Surg* 1955, 37-B:266–303.
13. Törmä T. Malignant tumours of the spine and spinal extradural space: A study based on 250 histologically verified cases. *Acta Chir Scand (Suppl)* 1957, 225:1–176.