

# Gait adaptations in patients with longstanding hip fusion

A Thambyah, HT Hee, S Das De, SM Lee

Department of Orthopaedic Surgery, National University of Singapore, Singapore

---

## ABSTRACT

**Purpose.** To examine the long-term effects of hip arthrodesis in terms of gait adaptations.

**Methods.** Motion analysis was performed on 9 patients who underwent unilateral hip arthrodesis between 1979 and 1991. A standard clinical gait analysis 3-dimensional model for the lower limb was used to calculate the effect of the fused hip on walking, compared with the contralateral normal hip.

**Results.** Significant ( $p < 0.05$ ) gait adaptations noted in the fused side were, compensatory hip hiking during the swing-phase, a 24% reduction in hip adduction moment, a 37% decrease in genu-varus moment, 80% reduced hip power, and excessive pelvic tilt.

**Conclusion.** It appears that the excess pelvic tilt observed was to achieve relative hip extension via

increased relative lumbar lordosis, while the decreased coronal plane moments of the hip and knee observed were to reduce joint loading on the affected side.

**Key words:** arthrodesis; gait; hip joint

---

## INTRODUCTION

Hip arthrodesis surgery is designed to cause a bridge of bone to develop across the hip socket, joining the ball and the socket of the hip joint. The aim is to remove the hip joint and replace it with a bony bridge. Indications for hip fusion include situations where a joint has been severely damaged and movement must be eliminated. Hip fusion is particularly relevant in infections of the hip joint and arthritis of the hip joint in very young individuals, for whom hip replacement

would not be the most appropriate procedure. The surgical procedure involves making an incision in the hip joint, following which cartilage from the hip is removed. The bone surfaces are then positioned and held in place by pins or plates until new bone can grow across the remaining gap, fusing the hip joint. When the hip has been repaired with plates or screws, a physiotherapist often assists rehabilitation, specifically with respect to ambulation and muscle strengthening. Weightbearing on the hip is not permitted until the hip has completely fused. Ultimately, the result is a painless or nearly painless hip joint, which is capable of full weightbearing, and of withstanding very vigorous activity. Problems associated with hip fusion include possible pain, functional impairment, and degeneration in the neighbouring joints, such as the contralateral hip, both knees, and the lumbar spine. These developments tend to occur over a long period, however.

If the motion or load-bearing capacity of the hip joint is reduced, alterations in the motion and load at other joints of the lower extremities and back may occur.<sup>1</sup> Loading at the hip joint, as well as the demands placed on the surrounding musculature and soft tissues, is largely influenced by the kinetics and kinematics of gait, as measured externally via motion analysis techniques.<sup>1</sup> For instance, reduced moments reflect decreased muscle force and decreased load on the hip joint in the absence of increased antagonistic muscle activity, and may represent a type of pain-avoidance mechanism.<sup>1</sup>

Few studies on gait analysis of patients with hip problems have attempted to relate gait adaptations to the patients' clinical characteristics.<sup>2,3</sup> To date, there has been little quantifiable data available defining the characteristics of walking in patients with long-term hip fusion. A better understanding of various gait adaptations in patients with fused hips may provide insight to address clinical concerns on the potential long-term effects of hip arthrodesis. The objective of this study was to examine the effects of a long-term fused hip on walking, comparing the fused hip with the contralateral unfused hip in individual patients who had previously undergone hip arthrodesis.

## PATIENTS AND METHODS

11 patients underwent arthrodesis of the hip at the National University Hospital, Singapore, between 1979 and 1991. In 1999, attempts were made to recall these patients for gait and clinical evaluation, with the help of the Immigration Department in Singapore. Two patients could not be located. Nine patients agreed to

take part in the study, including 7 men and 2 women. The average age of the patients at the time of surgery was 37.6 years (range, 28–54 years). The average follow-up period was 14.8 years (range, 8–20 years). Arthrodesis of the hip was performed for primary osteoarthritis in 3 patients, post-traumatic arthritis in 3 patients, tuberculous arthritis in 2 patients, and septic arthritis in one patient. The position of the fused hip was 30° flexion, neutral (abduction/adduction), 10° to 15° external rotation. Clinical outcome was graded using the Harris hip score.<sup>4</sup>

Gait analysis was performed using reflective markers placed on key anatomical landmarks. These were then tracked in space and time via retro-reflective infra-red light-detecting cameras (TM86; Vicon Motion Systems Ltd, Oxford, UK), as the patient walked over a force platform. Each patient was fitted with 17 skin markers, following a typical gait analysis protocol as outlined by the manufacturers of the gait analysis system and described previously.<sup>5</sup> Briefly, the markers were placed on selected anatomic features on the left and right sides, that is, on the anterior superior iliac spine, the greater trochanter, tibial tuberosity, fibula head, lateral malleolus, 5th metatarsal base, mid-heel, the calcaneum, and the posterior pelvis. A Kistler force platform (Kistler Instrumente AG, Winterthur, Switzerland) was used to obtain ground reaction forces at foot to ground contact. An Adtech Motion Analysis System (AMASS; Adtech, Adelphi, US) and a Vicon Clinical Manager (Vicon Motion Systems Ltd, Oxford, UK) were used in the analysis of the gait data. The mathematical model used to calculate joint motion and moments was based on the standard clinical model used in the video motion analysis system.<sup>6</sup> The objective was to assess the deviation caused by the fused hip to the kinematics and kinetics of a normal gait pattern. The hip joint on the fused side was thus assumed to exist, and motion and kinetics were calculated for that side as calculated for the normal, unaffected contralateral hip. The null hypothesis was that the calculated kinematics and kinetics of the fused hip would be no different from those of the contralateral side. The paired gait analysis data of the contralateral and fused limbs were compared for the 9 patients, and peak values observed were tested for significant differences using the paired *t* test, with  $p < 0.05$  considered statistically significant.

## RESULTS

Clinical evaluation using the Harris hip score (mean score,  $88 \pm 7.3$ ) revealed that all patients were relatively

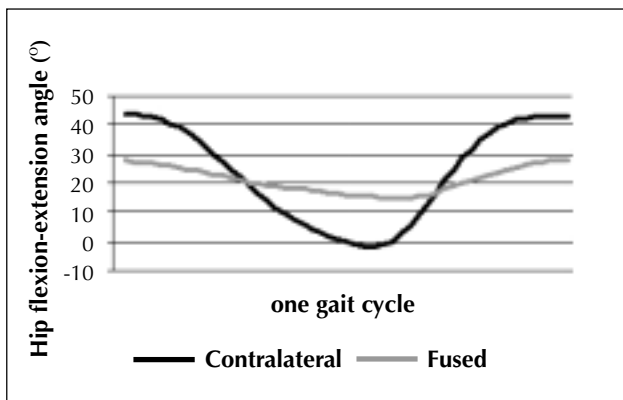
pain-free and had adapted well to the limitations imposed by the fused hip. Radiographs of the contralateral hip of these patients did not reveal any signs of degenerative changes. Similarly, the knees, sacroiliac joints, and lumbosacral spines of these patients did not show any evidence of arthritic changes.

The model from the Vicon Clinical Manager system used in this study to calculate joint kinematics and kinetics assumes a normal hip.<sup>6</sup> While the normal contralateral side produced gait patterns that were similar to normative data, the fused side showed significant ( $p < 0.05$ ) and consistent changes. Changes identified in the fused hip compared with the normal contralateral hip were as follows: compensatory hip hiking during the swing-phase, larger hip abduction in the stance-phase, a 24% reduction in hip adduction moment, a 37% decrease in genu-varus moment, 30% reduced muscle demand in hip extensors during stance, a 40% reduced demand on hip flexors at toe-off, a 95% reduced knee extensor muscle moment,

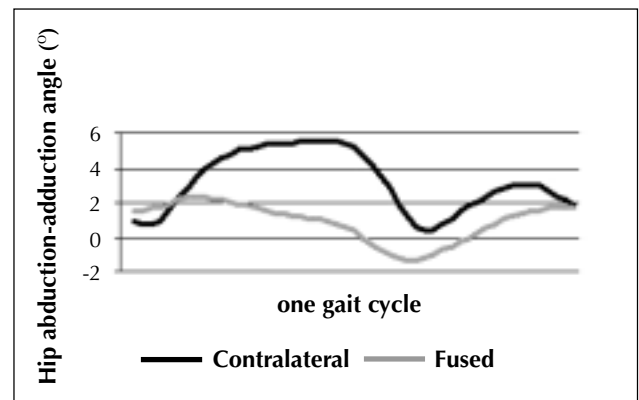
80% reduced hip power, and excessive pelvic tilt (Figs. 1–8).

### DISCUSSION

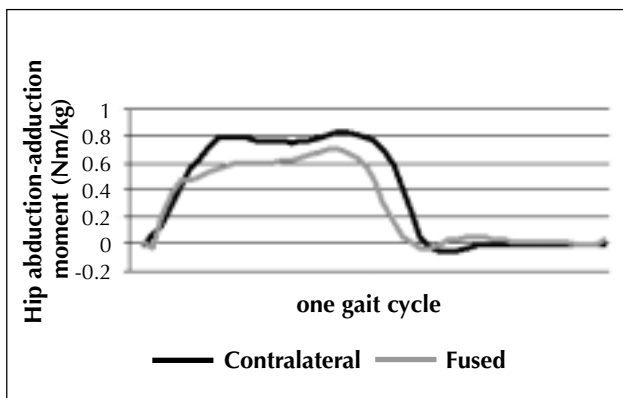
The model used in this study to calculate the lower limb kinematics and kinetics for the fused side assumes the presence of a hip joint, albeit one that is not normal. The results indicate that while the normal hip displays a regular gait pattern, using the same mathematical model the fused hip showed significant and consistent changes. In general, motion was restricted and joint loading reduced in the fused hip, and this was consistently measured using the standard gait model. To the authors' knowledge, this is the first study to analyse the various gait adaptations of patients after longstanding hip fusion. Although there have been reports on gait analysis of patients with osteoarthritis of the hip,<sup>1,7</sup> as well as in patients following total hip arthroplasty,<sup>7</sup> little attention has been devoted



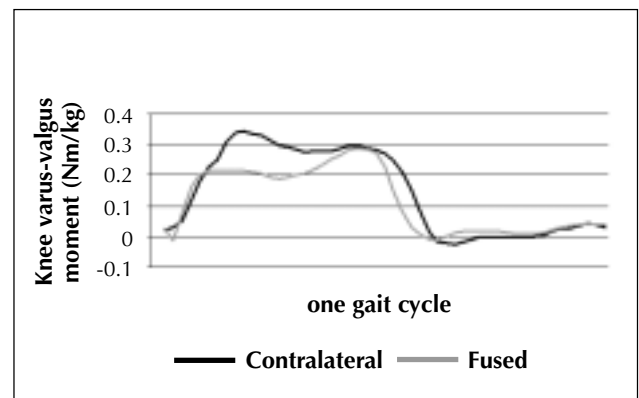
**Figure 1** Hip flexion (+) and extension (-) angles showing reduced range of motion in the fused hip ( $p < 0.05$ ).



**Figure 2** Hip adduction (+) and abduction (-) angles, showing compensatory hip hiking during the swing-phase and larger hip abduction angles in the stance-phase (T-gait) [ $p < 0.05$ ].



**Figure 3** Hip adduction (+) and abduction (-) moment showing a 24% reduction in hip adduction moment ( $p < 0.05$ ).



**Figure 4** Knee varus (+) and valgus (-) moment showing a 37% decrease in genu-varus moment ( $p < 0.05$ ).

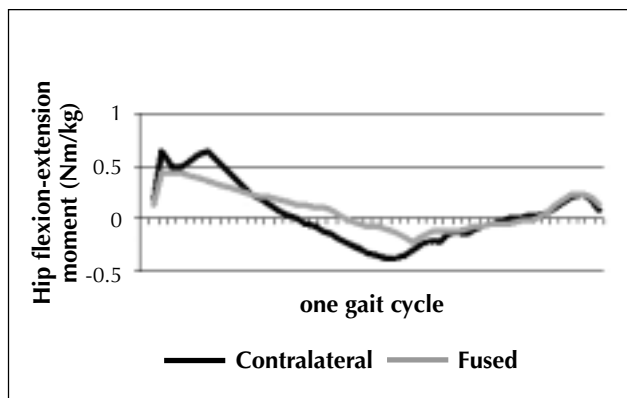
to the study of the gait patterns of patients with longstanding arthrodesis of the hip.

Longstanding arthrodesis of the hip often causes pain, functional impairment, and degeneration in neighbouring joints, including the ipsilateral knee, sacroiliac joint, and lower lumbar spine.<sup>8-11</sup> Patients with arthrodesed hips may present with knee or lower back pain, while their fused hips are painless and stable, and often allow walking without assistive devices.<sup>1</sup>

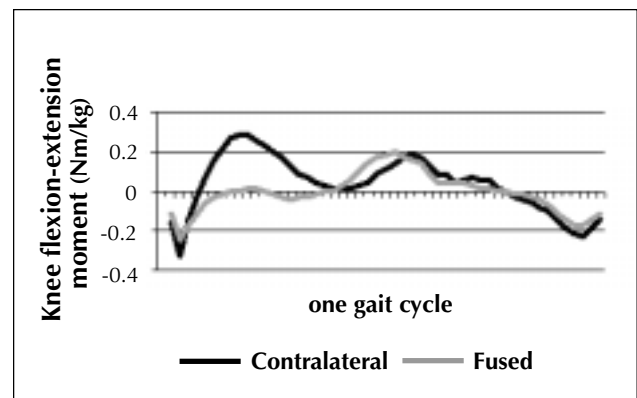
The gait adaptation observed in the present study addresses the issue of whether gait adaptation occurs to prevent painful weightbearing, or simply to achieve the most efficient gait. Patients did not report pain on weightbearing, but there was a severe restriction in the range of motion evident in the affected hips. There were some positions that the affected hips simply could not engage in for purely mechanical reasons. This, together with the particular position of the fusion, in the authors' view, resulted in an alteration

in the mechanical function of the hip and adjacent joints during gait. Hip flexion-extension motion was hampered, and consequently the adaptation facilitated 'pseudo' hip flexion-extension by other means.

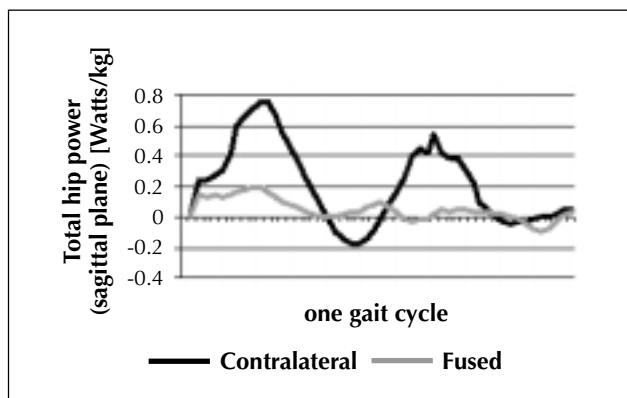
The compensatory motion with pelvic tilt appears most likely aimed at achieving relative hip extension via increased relative lumbar lordosis. This finding is similar to that found in a study on gait patterns of patients with osteoarthritis of the hip.<sup>2</sup> These authors reported an increase in anterior-posterior pelvic tilt from increased lumbar flexion-extension, and identified this as a method of compensation for the limited range of motion of the hip during gait. They concluded that increased pelvic and spinal excursion to compensate for loss of motion of the hip joint might contribute to an increased incidence of back pain. None of the patients in the current study with longstanding hip fusion developed chronic lower back pain or had degenerative changes of the lumbar spine on evaluation, however. Possibly a longer



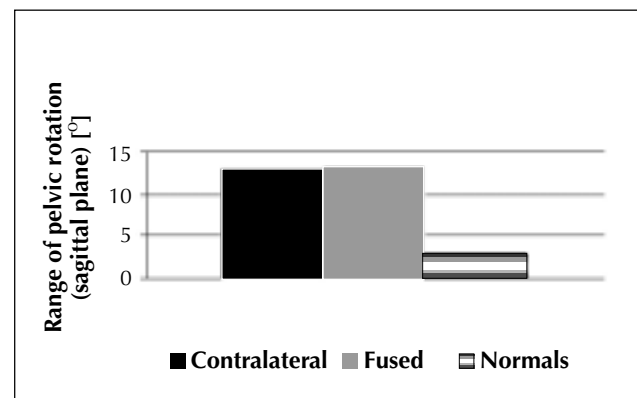
**Figure 5** Hip flexion (+) and extension (-) moments showing 30% reduced muscle demand in hip extensors during stance and a 40% reduced demand on hip flexors at toe-off.



**Figure 6** Knee flexion (+) and extension (-) moments showing 95% reduced flexion moment i.e. reduction in knee extensor muscle activity ( $p < 0.05$ ).



**Figure 7** Hip power generation (+) and absorption (-) showing 80% reduced hip power ( $p < 0.05$ ).



**Figure 8** Gait of patients with a fused hip shows excessive pelvic tilting compared with the gait of normal subjects (data obtained from a database) [ $p < 0.05$ ].

follow-up period may have detected lower back symptoms attributable to degeneration of the lumbar spine.

Differences were also identified for the moment of force in the sagittal plane in the current study. During stance, the fused hip exhibited reduced hip flexion moment and a 30% reduction in muscle demand in the hip extensors. The ipsilateral knee showed a reduction in knee flexion moment, and a 95% reduction in knee extensor muscle moment (almost quadriceps avoidance gait). One study of gait patterns in patients with osteoarthritis of the hip reported a reduced peak extension moment of the hip, which the authors interpreted as related to pain.<sup>1</sup> The reduced hip extension moment seen would have shifted the centre of mass forward, leading to reduced knee flexion moment during that portion of stance. Another study on gait analysis of women following total hip arthroplasty, and found a significant decrease of 20% in hip extensor moment of force during early stance, and that this finding was correlated with a significant decrease in gait speed of 14%.<sup>12</sup>

The decrease in adduction moments about the hip, and varus moments about the knee, seen in the coronal

plane, may help to reduce joint loading. This may be a mechanism that delays degeneration of the ipsilateral knees in patients with longstanding fusion of the hip. Decreased adduction moment of the hip has also been reported in patients with osteoarthritis of the hip.<sup>1</sup> Shifting the centre of mass more laterally over the hip joint would not only reduce the adduction moment of the hip, but also the varus moment of the ipsilateral knee. Another study reported a decrease in the abductor moment of force that persisted irrespective of gait speed, suggestive of weakness of the hip abductor muscles.<sup>12</sup>

The gait mechanisms observed in our patients with longstanding hip fusion and good clinical outcome provide the biomechanical rationale that these adaptations may be attempts to reduce degenerative changes in the spine and knees. The apparent reduction in muscle usage, in particular of the quadriceps of the ipsilateral leg, warrants special attention in terms of the long-term effects on muscle strength. It is our view that rehabilitative strategies in patients with arthrodesis of the hip should focus on strengthening the hip abductors and extensors, as well as on strengthening the knee extensors.

## REFERENCES

1. Hurwitz DE, Hulet CH, Andriacchi TP, Rosenberg AG, Galante JO. Gait compensations in patients with osteoarthritis of the hip and their relationship to pain and passive hip motion. *J Orthop Res* 1997;15:629–35.
2. Murray MP, Gore DR, Clarkson BH. Walking patterns of patients with unilateral hip pain due to osteo-arthritis and avascular necrosis. *J Bone Joint Surg Am* 1971;53:259–74.
3. Olsson E. Gait analysis in hip and knee surgery. *Scand J Rehabil Med Suppl* 1986;15:1–55.
4. Harris WH. Traumatic arthritis of the hip after dislocation and acetabular fractures: treatment by mold arthroplasty. An end-result study using a new method of result evaluation. *J Bone Joint Surg Am* 1969;51:737–55.
5. Goh JC, Bose K, Khoo BC. Gait analysis study on patients with varus osteoarthrosis of the knee. *Clin Orthop* 1993;294:223–31.
6. Kadaba MP, Ramakrishnan HK, Wootten ME. Measurement of lower extremity kinematics during level walking. *J Orthop Res* 1990;8:383–92.
7. Tanaka Y. Gait analysis of patients with osteoarthritis of the hip and those with total hip arthroplasty. *Biomed Mater Eng* 1998;8:187–96.
8. Callaghan JJ, Brand RA, Pedersen DR. Hip arthrodesis. A long term follow-up. *J Bone Joint Surg Am* 1985;67:1328–35.
9. Perugia L, Santori FS, Mancini A, Manili M, Falez F. Conversion of the arthrodesed hip to a total hip arthroplasty. Indications and limitations. *Ital J Orthop Traumatol* 1992;18:145–53.
10. Sofue M, Kono S, Kawaji W, Homma M. Long term results of arthrodesis for severe osteoarthritis of the hip in young adults. *Int Orthop* 1989;13:129–33.
11. Sponseller PD, McBeath AA, Perpich M. Hip arthrodesis in young patients. A long-term follow-up study. *J Bone Joint Surg Am* 1984;66:853–9.
12. Perron M, Malouin F, Moffet H, McFadyen BJ. Three-dimensional gait analysis in women with a total hip arthroplasty. *Clin Biomech (Bristol, Avon)* 2000;15:504–15.