

How often should computed tomographic scans following cross-table lateral cervical films be performed?

T Suzuki, N Morimura, M Sugiyama

Critical Care and Emergency Medical Center, Yokohama City University School of Medicine, Yokohama, Japan

T Kitahara, K Soma

Department of Traumatology and Critical Care Medicine, Kitasato University School of Medicine, Sagamihara, Japan

ABSTRACT

Purpose. In patients with blunt trauma, a cross-table lateral cervical (CTL) film is followed by a focused computed tomographic (CT) scan of the cervical spine to assess an area inadequately delineated by common techniques and suspected injuries, based on recent guidelines in the United States. The purpose of this study was to calculate the frequency of such supplemental CT scans and to evaluate the efficacy of the recent guidelines describing the use of CTL films as an indicator of supplemental focused CT scanning in Japan.

Methods. A review of CTL films was performed. 100 initial CTL films with injuries and another 100 films without injuries were evaluated for the lowest ver-

tebra visualised on the CTL film. The frequency of abnormal signs on the CTL films was then examined.

Results. Technically adequate CTL films that showed the upper border of the T1 vertebra were not obtained from 70 patients with injuries and 63 patients without injuries. 88 patients with injuries and 28 patients without injuries had abnormal findings on CTL films. Overall, 97 patients with injuries and 74 patients without injuries should have received supplemental CT scans.

Conclusion. CTL films require frequent supplemental use of CT, even for patients without cervical spine injuries. Thus, the guidelines that consider CTL film as an indicator of the necessity for CT scanning are not efficient and need revision.

Key words: cervical vertebrae; guidelines; radiography; spinal injuries; tomography, x-ray computed

INTRODUCTION

Appropriate and emergency evaluation of cervical spine injuries in patients with blunt trauma is a challenging task for the trauma team. A cross-table lateral cervical (CTL) film may show normality in 5% to 15% of the patients who indeed have cervical spine injuries.¹⁻³ On the other hand, computed tomographic (CT) scans of the cervical spine have been shown to be more sensitive in identifying cervical spine injuries.^{4,5} Thus, recent guidelines suggest that the plain radiograph followed by focused CT scanning through suspicious and inadequately visualised areas is a sufficient screening tool.⁶⁻⁸

The frequency of performing CT scans in conformity with these strategies is important for accurate evaluation of the efficacy of the guidelines. Thus, the present analysis was undertaken to determine the exact frequency of supplemental CT scans required inevitably from CTL films, based on these guidelines.

MATERIALS AND METHODS

Films that show the upper border of the T1 vertebra are described as technically adequate. The lateral view of the cervical spine involved the use of portable CTL film with bilateral caudal arm traction in the resuscitation area. Technically inadequate films that failed to show the upper border of the T1 vertebra were not repeated. CTL films were not obtained in the initial evaluation of alert and asymptomatic patients.

Data from patients with injuries were obtained retrospectively through admission records from 1 January 1994 to 31 December 2000. The initial CTL films of 100 patients with cervical spine injuries involved a total of 141 vertebral fractures or dislocations (including 33 multi-level vertebral injuries). The most frequently injured vertebra was C5. The incidence of injury of the 2 lowest cervical vertebrae (C6 and C7), which often cannot be visualised on CTL films, was 22.7%. The anatomical segments of the cervical spine injuries are shown in Fig. 1.

The patients with injuries included all definite cervical fractures or dislocations with the exception of those who had attempted to hang themselves, were younger than 15 years old, or had been transferred from a different hospital after initial treatment. Plain radiography, tomography, CT scanning, magnetic resonance imaging, or autopsy confirmed fractures or dislocations. Questionable fractures

or dislocations were excluded. We recorded the levels and types of injuries. In the present study, the first CTL films were used for evaluation and read by an orthopaedist.

Data from patients without injuries were obtained from the admission records of another 100 consecutive patients with blunt trauma. These patients had neck symptoms or mental changes but sustained no injuries from 1 January 2000 to 26 August 2000. The patients had been followed up for 3 to 14 months. They had no evidence of cervical fractures or dislocations.

We compared patients with and without injuries in regard to the technical adequacy of the CTL films, in particular, the visualisation of the area of the lowest vertebra. We hypothesised that in patients with injuries, this area is narrower than that in patients without injuries due to pain or muscle spasm. The lowest vertebra was considered visualised if the upper border of the adjacent lower vertebra was identified. The Chi squared test and Mann-Whitney *U* test were used to determine differences between groups. Statistical analysis of data pertaining to the lowest vertebra was performed using Mann-Whitney *U* test. Statistical significance was established at $p < 0.05$. Abnormal signs on the CTL films that indicated the need for subsequent CT scans are defined in the Box.

RESULTS

The patients' data are shown in Table 1. Patients with injuries included 76 men and 24 women, with

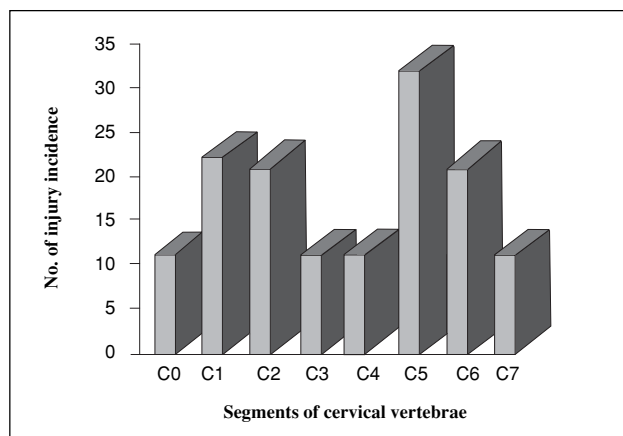


Figure 1 Distribution of the injured vertebrae. C0 denotes atlanto-occipital dislocation. The most frequently injured vertebra was C5. The incidence of injury of the 2 lowest cervical vertebrae (C6 and C7), which often cannot be visualised on CTL films, was 22.7%.

Table 1
Comparison of patients with and without cervical spine injuries

	With injuries (n=100)	Without injuries (n=100)	p value	Test
Age* (years)	41.1±17.2	41.9±18.1	NS [†]	Mann-Whitney <i>U</i> test
No. of men	76	72	NS	Chi squared test
No. of women	24	28	NS	Chi squared test
Glasgow coma score*	9.5±5.6	9.6±5.0	NS	Mann-Whitney <i>U</i> test
Injury severity score*	26.3±17.6	18.8±12.1	0.007	Mann-Whitney <i>U</i> test

* Data presented as mean±standard deviation

[†] NS not significant

Box
Abnormal signs on the films that necessitated
subsequent CT scans

Fracture line¹⁷
Deformity of vertebral body (except for spondylotic change)¹⁷
Widening of the interspinous distance¹⁸
Anterior or posterior translation of vertebral body >2 mm¹⁸
Increased angulation between the adjacent segment >11°¹⁸
Rotation of the facets¹⁹
Retropharyngeal soft-tissue interval >7 mm at the C2 level
or >22 mm at the C5 level²⁰
Atlantodental interval >3 mm²¹
Abnormalities identified by the X-line method²²

a mean age of 41.1 years (range, 16–75 years). Patients without injuries included 72 men and 28 women, with a mean age of 41.9 years (range, 16–82 years). The mean Glasgow coma score was 9.5 (range, 3–15) for those with injuries and 9.6 (range, 3–15) for those without injuries. The mean injury severity score was 26.3 (range, 8–75) in the group with injuries, and 18.8 (range, 5–59) in the group without injuries. No significant difference was identified except the injury severity score (Table 1).

Technically adequate lateral cervical spine films that visualised the upper border of the first thoracic vertebra were not obtained from 70 patients with injuries and 63 patients without injuries, a difference that is not statistically significant (Fig. 2). Among the 100 patients with injuries, 88 had abnormal signs on the CTLC films (88 true positives); however, the remaining 12 patients did not present with any abnormal signs and their CTLC films appeared completely normal. In contrast, the CTLC films of 72 patients without injuries appeared normal (72 true negatives) and 28 had abnormal signs (all these 28 films were regarded as abnormal because of the widening of the retropharyngeal space). Thus, CTLC films, according to the criteria listed above, had a sensitivity of 88% and a specificity of

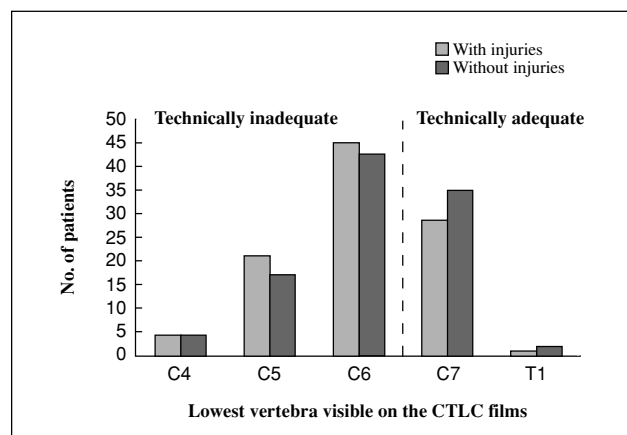


Figure 2 Distribution of the lowest vertebra that was visualised on the CTLC films. Statistical analysis was performed using Mann-Whitney *U* test. No significant difference was identified ($p=0.27$).

72%. Overall, 97 patients with injuries and 74 patients without injuries should have received supplemental CT scans because of inadequate films and abnormal signs (Table 2).

DISCUSSION

We have shown that the CTLC films evaluated according to the said criteria have a sensitivity of 88% and a specificity of 72%. This result is similar to other reports, which have shown that the sensitivity of CTLC film is approximately 85% with a specificity approaching 50%.^{1,9,10} Plain radiography alone is often of limited diagnostic value, because technically adequate plain radiography is not always obtained in the initial evaluation and repeated plain radiography is not always successful.^{4,11,12}

Because our centre only accepts critically injured patients, the injury severity score is usually high

Table 2
Statistics of patients performed CTLC films

	With abnormal sign Inadequate visualisation	With abnormal sign Adequate visualisation	Without abnormal sign Inadequate visualisation	Total
Patients with injuries	61	27	9	97
Patients without injuries	17	11	46	74

for our patients. As the clinical examination of such critically injured patients is not reliable,¹³ the combined use of plain radiography and CT scan has been adopted to increase the sensitivity of identifying cervical spine injuries.^{3,7,14} Recently, the Advanced Trauma Life Support and the Eastern Association for the Surgery of Trauma have suggested that focused CT scans through the lower cervical spine should be obtained if this area cannot be visualised on plain radiographs.^{6,8}

In the present study, adequate visualisation was achieved in only 37% of patients without injuries, implying that 63% of patients with blunt trauma who sustain no cervical injury must undergo CT scanning in the initial evaluation only to counteract the technical inadequacy of plain radiographs. The described incidence of inadequate films varies from 25.9% to 47%.^{1,10,15} This study detected a high incidence of inadequate lateral views from the initial evaluation, possibly because our study excluded alert and asymptomatic patients. Recently, the NEXUS studies have suggested that patients who are alert, non-intoxicated, and asymptomatic be released from cervical spine precautions without any radiographic investigation.¹³ Thus, the incidence detected in the present study may be more meaningful for clearance of the cervical spine injuries. Having said that, the possibility that the difficulty in visualisation of the lower cervical spine may be associated with the anatomical characteristics of Mongoloids cannot be excluded.

Overall, 97 patients with injuries and 74 patients without injuries should have received supplemental CT scans due to technically inadequate films and

abnormal signs. We believe that if CTLC films require supplemental CT scans in more than 75% of all obtunded or symptomatic blunt trauma patients, the films are probably not an appropriate guideline. We further believe that these guidelines using a CTLC film as an indicator of supplemental focused CT scanning are neither efficient nor cost-effective today.¹⁶ Blackmore et al.¹⁶ reported that different guidelines that emphasise the clinical features and mechanism of the injury can identify the low-risk and high-risk groups of patients. The lower-risk group proceeds to plain radiograph only while the higher-risk group requires mandatory full cervical spine CT scan irrespective of findings on the CTLC film. Blackmore et al.¹⁶ further showed that the screening CT was performed in only 16% of blunt trauma patients, but the rate of missed cervical injuries was 0.2%. Although we believe that such guidelines should apply to critically injured patients,⁵ further studies are required to clarify this issue.

CONCLUSION

Adequate visualisation of the lower cervical spine on plain radiograph was difficult. CTLC films require frequent use of subsequent CT scanning to clearly visualise the cervical spine or to identify cervical injuries. If CT scans are to be performed for most patients with blunt trauma, we believe that revised guidelines will be needed for the assessment of the cervical spine of obtunded or symptomatic blunt trauma patients.

REFERENCES

1. Ross SE, Schwab CW, David ET, DeLong WG, Born CT. Clearing the cervical spine: initial radiologic evaluation. *J Trauma* 1987;27:1055-60.
2. Shaffer MA, Doris PE. Limitation of the cross table lateral view in detecting cervical spine injuries: a retrospective analysis. *Ann Emerg Med* 1981;10:508-13.

3. Woodring JH, Lee C. Limitations of cervical radiography in the evaluation of acute cervical trauma. *J Trauma* 1993;34:32–9.
4. Acheson MB, Livingston RR, Richardson ML, Stimac GK. High-resolution CT scanning in the evaluation of cervical spine fractures: comparison with plain film examinations. *AJR Am J Roentgenol* 1987;148:1179–85.
5. Berne JD, Velmahos GC, El-Tawil Q, Demetriades D, Asensio JA, Murray JA, et al. Value of complete cervical helical computed tomographic scanning in identifying cervical spine injury in the unevaluable blunt trauma patient with multiple injuries: a prospective study. *J Trauma* 1999;47:896–903.
6. American College of Surgeons: Advanced Trauma Support Student Manual. Chicago, American College of Surgeons; 2001.
7. Banit DM, Grau G, Fisher JR. Evaluation of the acute cervical spine: a management algorithm. *J Trauma* 2000;49:450–56.
8. Practice parameters for identifying cervical spine injuries following trauma. EAST website: <http://www.east.org/tpg/chap3body.html>.
9. Doris PE, Wilson RA. The next logical step in the emergency radiographic evaluation of cervical spine trauma: the five-view trauma series. *J Emerg Med* 1985;3:371–85.
10. MacDonald RL, Schwartz ML, Mirich D, Sharkey PW, Nelson WR. Diagnosis of cervical spine injury in motor vehicle crash victims: how many X-rays are enough? *J Trauma* 1990;30:392–7.
11. Davis JW, Phreaner DL, Hoyt DB, Mackerzie RC. The etiology of missed cervical spine injuries. *J Trauma* 1993;34:342–6.
12. Spain DA, Trooskin SZ, Flancbaum L, Boyarsky AH, Noshier JL. The adequacy and cost effectiveness of routine resuscitation-area cervical-spine radiographs. *Ann Emerg Med* 1990;19:276–8.
13. Mower WR, Hoffman JR, Pollack CV Jr, Zucker MI, Browne BJ, Wolfson AB, et al. Use of plain radiography to screen for cervical spine injuries. *Ann Emerg Med* 2001;38:1–7.
14. Gerrelts BD, Petersen EU, Mabry J, Petersen SR. Delayed diagnosis of cervical spine injuries. *J Trauma* 1991;31:1622–6.
15. Cohn SM, Lyle WG, Linden CH, Lancey RA. Exclusion of cervical spine injury: a prospective study. *J Trauma* 1991;31:570–4.
16. Blackmore CC, Mann FA, Wilson AJ. Helical CT in the primary trauma evaluation of the cervical spine: an evidence-based approach. *Skeletal Radiol* 2000;29:632–9.
17. Kim KS, Rogers LF, Regenbogen V. Pitfalls in plain film diagnosis of cervical spine injuries: false positive interpretation. *Surg Neurol* 1986;25:381–92.
18. White AA 3rd, Panjabi MM. Update on the evaluation of instability of the lower cervical spine. *Instr Course Lect* 1987;36:513–20.
19. Scher AT. Unilateral locked facet in cervical spine injuries. *AJR Am J Roentgenol* 1977;129:45–8.
20. Miles KA, Finlay D. Is prevertebral soft tissue swelling a useful sign in injury of the cervical spine? *Injury* 1988;19:177–9.
21. Fielding JW, Hawkins RJ, Ratzan SA. Spine fusion for atlanto-axial instability. *J Bone Joint Surg Am* 1976;58:400–7.
22. Lee C, Woodring JH, Goldstein SJ, Daniel TL, Young AB, Tibbs PA. Evaluation of traumatic atlantooccipital dislocations. *AJNR Am J Neuroradiol* 1987;8:19–26.