

# Multiple carpometacarpal dislocations and an ipsilateral scapho-trapezium-trapezoid fracture-dislocation: A rare pattern of injury

SG Kirkham, RJ Gray  
Westmead Hospital, Sydney, Australia

---

## ABSTRACT

We report a rare case of simultaneous dorsal dislocation of 4 ulnar carpometacarpal joints and dorsoradial dislocation of the trapezium with an associated fracture of the scaphoid tuberosity. The injuries were diagnosed early and treated successfully with closed reduction and transfixation using Kirschner wires. The functional results were excellent at 17-month follow-up.

**Key words:** bone wires; carpal bones; dislocations; fractures, closed; metacarpus

---

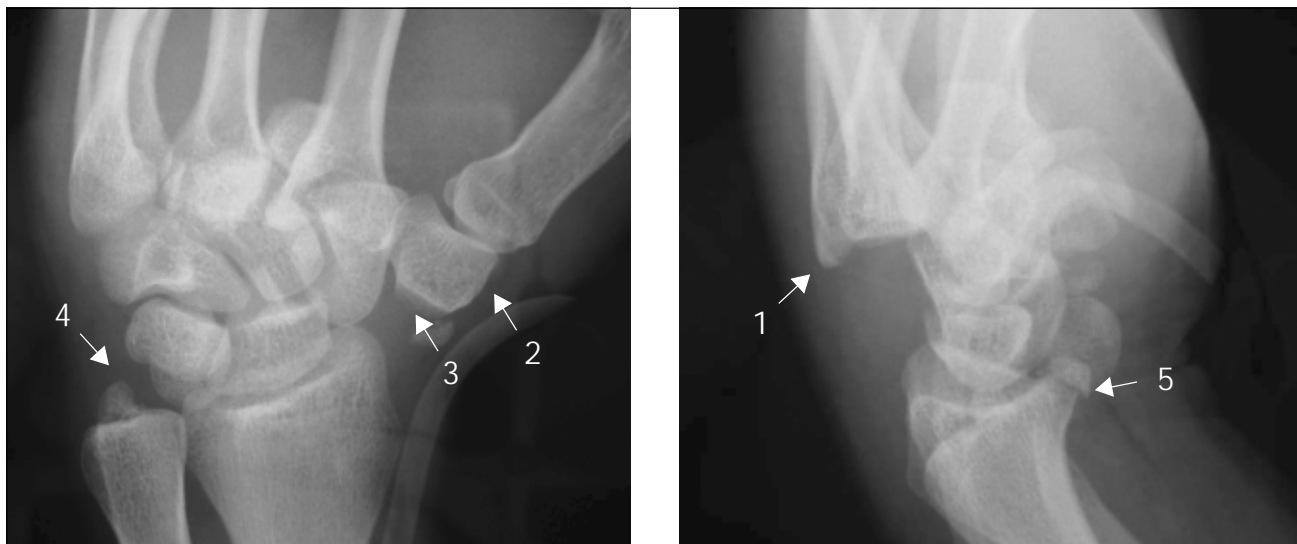
## CASE REPORT

A 23-year-old, right-handed, male motorcycle rider collided into the back of a truck at approximately

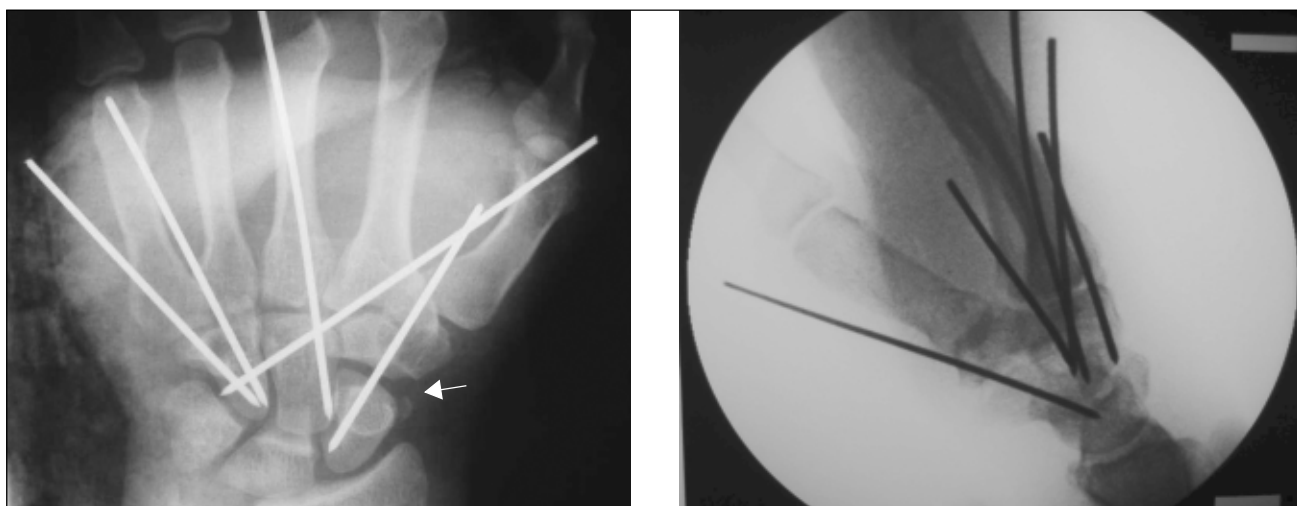
60 km/h. He was admitted to the Westmead Hospital in February 2001. He sustained compound fractures to his left forearm, a closed contralateral injury to his right wrist, and a deep laceration to his thigh. Computed tomography of his abdomen and pelvis showed a large pelvic haematoma. He subsequently became haemodynamically unstable and had an emergency aorto-iliac angiogram and embolisation of the distal internal pudendal artery.

Radiographs and computed tomography of his right wrist showed dorsal dislocation of 4 ulnar carpometacarpal joints, dorsoradial dislocation of the trapezium with associated fractures of the scaphoid tuberosity, volar lip of distal radius, and ulna styloid process. The thumb carpometacarpal, all metacarpophalangeal, and interphalangeal joints were intact (Fig. 1).

The second to fifth right metacarpals and trapezium were reduced closedly and transfixed with dorsal Kirschner wires the day after the injury (Fig. 2). An open reduction and internal fixation of the left radius and ulna with standard dynamic compression



**Figure 1** Anteroposterior and lateral views of the right wrist showing: (1) the dorsal dislocation of the second to fifth carpometacarpal joints, (2) the dorsoradial dislocation of the trapezium, the fractures of (3) the scaphoid tuberosity, (4) the styloid process of ulna, and (5) the volar lip of the distal radius.



**Figure 2** Post-reduction anteroposterior and lateral radiographs of the right wrist, with the second to fifth carpometacarpal joints reduced and transfixed with Kirschner wires. Note the reduced fragment of the scaphoid tuberosity (shown by arrow).

plates and osteosect bone grafting were performed at the same time. His injured right hand and wrist were protected with a rigid thermoplastic splint for a period of 6 weeks. Active finger and thumb exercises were encouraged under the supervision of a hand therapist.

At a follow-up after 17 months, our patient had a mean power grip strength of 35.2 kg in the treated right hand, compared to 32.4 kg in the uninjured left hand. His tip-to-tip pinch grip was 7 kg on the right and

6 kg on the left. He had full and painless range of motion of all his carpometacarpal joints in the right hand and the return of normal function.

#### DISCUSSION

The dorsal dislocation of 4 ulnar carpometacarpal joints with a concurrent dorsoradial dislocation of the

trapezium is an extremely rare injury. Pai et al.<sup>1</sup> reported a series of 20 patients with carpal bone dislocations, of whom one had a combination of injuries identical to those of our patient. As far as we are aware, this is the only reported case of a similar injury in the literature. Petersen et al.<sup>2</sup> reported simultaneous occurrence of fracture dislocation of 3 ulna carpometacarpal joints and dorsoradial dislocation of the trapezium.

Carpometacarpal joints have a complex anatomical configuration. The bases of the metacarpals articulate with each other and with the distal row of the carpal bones in an interlocking manner. Strong volar and dorsal interosseous ligaments, which span between the bases of the metacarpals and the carpometacarpal joints, further reinforce this bony architecture. The long extensors and flexors, along with the intrinsic muscles of the hand, provide dynamic stabilisation of the carpometacarpal joints. As a result, a great deal of energy and force is required to dislocate these joints. Hence, the concurrent dislocation of multiple joints is rare.<sup>3</sup>

The general consensus in the literature is that the dislocation of the carpometacarpal joints can occur either by a direct force on the bases of the metacarpals or by an indirect force transmitted via the metacarpal shafts. Our patient believes that he was gripping the motorcycle handle with an extended wrist when he crashed into the back of the truck. A significant amount of force would then transmit across the handle to the volar aspect of the bases of his second to fifth metacarpals and dislocated them dorsally. Sherlock<sup>3</sup>

postulated the mechanism by which the trapezium may be dislocated in a dorsoradial direction. When the first metacarpal is adducted at the carpometacarpal joint, the flexion forces and the axial compression forces are directed perpendicular to the dorsoradial dislocation of the trapezium, and may cause a fracture of the scaphoid tuberosity. Gripping a motorcycle handle tightly during impact would cause the first metacarpal to be flexed and adducted against the handle. This may explain the dorsoradial dislocation of the trapezium and the fractured scaphoid tuberosity in our patient.

Eichhorn-Sens et al.<sup>4</sup> described a series of 16 patients with carpometacarpal dislocation. They successfully treated the majority of these patients with closed reduction and temporary transfixation with Kirschner wires. Various methods have been described for the management of the dorsoradial dislocation of the trapezium.<sup>5-11</sup> These range from closed or open reduction and transfixation with Kirschner wires to extirpation of the trapezium. We successfully treated both the multiple carpometacarpal dislocation and the scapho-trapezium-trapezoid dislocation with closed reduction and temporary transfixation with Kirschner wires.

In conclusion, this case illustrates that this rare and complex injury can be treated successfully with early closed reduction of the affected joints, and stabilisation with Kirschner wires. This should be combined with a period of immobilisation followed by intensive hand therapy.

## REFERENCES

1. Pai CH, Wei DC, Hu ST. Carpal bone dislocations: an analysis of twenty cases with relative emphasis on the role of crushing mechanisms. *J Trauma* 1993;35:28-35.
2. Petersen MB, Nielsen PT, Nielsen LS. Simultaneous occurrence of trapezium-scaphoid-trapezoid dislocation and multiple carpometacarpal fracture dislocations. A case report. *Acta Orthop Scand* 1992;63:104-5.
3. Sherlock DA. Traumatic dorsoradial dislocation of the trapezium. *J Hand Surg Am* 1987;12:262-5.
4. Eichhorn-Sens J, Katzer A, Meenen NM, Rueger JM. Carpo-metacarpal dislocations injuries [in German]. *Handchir Mikrochir Plast Chir* 2001;33:189.
5. Ahmad MH, Midha VP. Dislocation of the trapezium: open reduction by the dorsal approach. *Injury* 1991;22:410-1.
6. Brewood AF. Complete dislocation of the trapezium: a case report. *Injury* 1985;16:303-4.
7. Goldberg I, Amit S, Bahar A, Seelenfreund M. Complete dislocation of the trapezium (multangulum majus). *J Hand Surg Am* 1981;6:193-5.
8. Ichikawa T, Inoue G. Complete dislocation of the trapezium. Case report. *Scand J Plast Reconstr Surg Hand Surg* 1999;33:335-7.
9. Mestdagh H, Butruille Y, Butin E, Urvoy P, Perlinski S, Maynou C. Scaphoid-trapezium-trapezoid dislocation. 5 cases [in French]. *Ann Chir Main Memb Supe* 1991;10:280-5.
10. Tawil HJ, Semaan I, Lignac F, Kuhlmann JN. Dorsal trapezo-scaphoid luxation. A case report. *Ann Chir Main Memb Super* 1993;12:213-9.
11. Vente JP, de Ruitter K. Complete dislocation of the trapezium multangulum majus. *Neth J Surg* 1983;35:33-5.