

Active mobilisation after flexor tendon repair: comparison of results following injuries in zone 2 and other zones

LK Hung, KW Pang

Department of Orthopaedics and Traumatology, The Chinese University of Hong Kong, Prince of Wales Hospital, Hong Kong

PLC Yeung, L Cheung

Department of Physiotherapy, The Chinese University of Hong Kong, Prince of Wales Hospital, Hong Kong

JMW Wong, P Chan

Department of Occupational Therapy, The Chinese University of Hong Kong, Prince of Wales Hospital, Hong Kong

ABSTRACT

Purpose. To prospectively study the role of active mobilisation after flexor tendon repair.

Methods. The standard modified Kessler's technique was used to repair 46 digits in 32 patients with flexor tendon injuries. Early active mobilisation of the repaired digit was commenced on the third postoperative day. Range of movement was monitored and recovery from injury in zone 2 was compared with injury in other zones.

Results. There were 24 and 22 injuries in zone 2 and other zones respectively. The total active motion score of the American Society for Surgery of the Hand was measured. Patients with zone-2 injuries achieved similar results to those with other-zone injuries apart from a 3-week delay in recovery. The final results were good to excellent in 71% and 77% of zone-2 and other-zone cases respectively ($p < 0.05$). There were 2 ruptures in zone-2 and one rupture in zone-3 repairs (6.5%).

Conclusion. Preliminary results of this study showed that active mobilisation following flexor tendon repair provides comparable clinical results and is as safe as conventional mobilisation programmes although recovery in patients with zone-2 injury was delayed.

Key words: rehabilitation; tendon injuries

INTRODUCTION

Mobilisation following flexor tendon repair is essential for healing and repair. It has been shown experimentally that early motion stimulates tendon healing and decreases adhesion.¹⁻⁴ Kleinert et al.⁵ and Lister et al.⁶ were among the first to report remarkable clinical results using active extension-passive flexion mobilisation with the aid of a dynamic traction splint. Similar results were subsequently reported by different authors.^{7,8} Nonetheless, flexion contracture of the finger may develop, and it has been difficult to achieve

consistent flexion of the distal interphalangeal joint. The problem is caused by poor differential gliding between the superficialis and profundus tendons in zone 2 with subsequent adhesion formation. The palmar pulley modification of the Kleinert splint may increase movement at the distal interphalangeal joint but this modification is not applicable in all cases and may actually aggravate flexion contracture. Active mobilisation of the injured finger will solve these problems because it provides differential gliding between the tendons in a normal physiological manner.⁹ Several studies have reported the results of early active mobilisation and active extension-passive flexion mobilisation.¹⁰⁻¹⁶ We developed our own protocol of active mobilisation following tendon repair and examined the serial recovery of finger movement. The progress of rehabilitation between zone-2 and other-zone injuries was compared.

MATERIALS AND METHODS

A one-year consecutive series of 32 patients (28 males and 4 females) aged between 12 and 61 years (mean, 26 years) with flexor tendon injuries in all zones of the hand were admitted to the Prince of Wales Hospital, Hong Kong and prospectively studied. All patients had unilateral injuries: 20 involved the left hand and 12 involved the right hand. Of 46 injured digits, 24 (52%) were injured in zone 2 and 22 (48%) in other zones (zone 1, n=5; zone 3, n=9; and zone 5, n=8). Sharp-cut injuries accounted for 78%. The remaining 22% were untidy injuries caused by crushing or machinery. Uncomplicated fractures or nerve injuries were also

Table 1
Associated injuries

	Zone 2	Other zones	Total (%)
Digital nerve	10	6	16 (67%)
Fracture	2	0	2 (8%)
Skin loss	1	1	2 (8%)
Soft-tissue injury	1	3	4 (17%)

included, but extensor tendon injuries and finger replantations were excluded. The most common associated injury was a cut digital nerve (Table 1).

Tendons were repaired by the modified Kessler's method using a 2-strand core suture with 4/0 nylon and a circumferential running suture with 6/0 nylon. Both superficialis and profundus tendons were repaired and the flexor tendon sheath repaired if feasible. A compression dressing was applied for 2 days together with a dorsal plaster slab to maintain the wrist in 40° flexion and extension block of the metacarpophalangeal joints at 90°. The hand was elevated. On the third postoperative day, the compression dressing was removed and, if wound healing was uncomplicated, a light dressing was applied. A thermoplastic dorsal splint was used to maintain the wrist in 40° flexion, the metacarpophalangeal joints at 70° flexion and dorsal extension block for the fingers at 0°. The fingers were unobstructed and able to move freely (Fig. 1). An extension platform support to the fingers was usually given at night to support and immobilise the interphalangeal joints in extension.

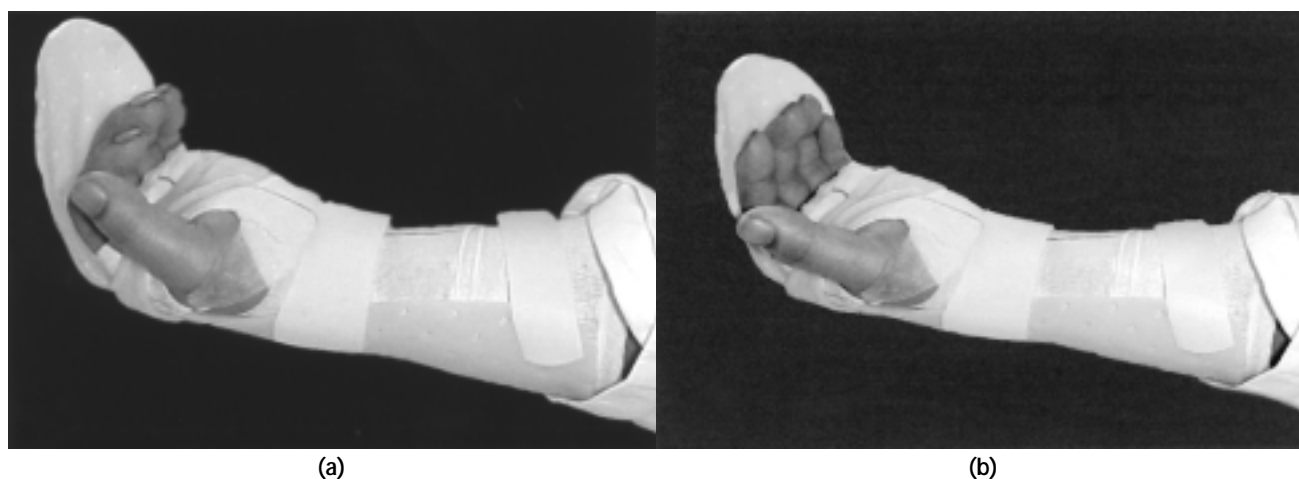

Figure 1 Mobilisation of the fingers while wearing a dorsal splint: (a) gentle flexion and (b) gentle extension of the fingers.

Programme of active mobilisation

All patients commenced active finger mobilisation, supervised by an experienced therapist. The fingers were initially mobilised with the wrist splint in place. There was normally 30° to 40° flexion of the interphalangeal joints at rest. The mobilisation programme consisted of gentle flexion of the interphalangeal joints from this resting position for a further 20° (flexion range, 30°–50°), followed by gentle slow extension to 0° (full extension). Patients were then instructed to relax to allow passive recoil of the fingers back to the resting position. This cycle of movement was repeated slowly with time breaks in between. The number of movements was arbitrary: usually 5 times with 2 to 3 sessions on the first day. The range of flexion as well as the number of movements and sessions were slowly increased according to the condition and progress of the patient.

The therapist also carried out 'tenodesis mobilisation' of the wrist and hand. The wrist splint was removed and the patient was instructed to relax. The wrist was gently flexed and extended without resistance being applied to the fingers. The fingers were flexed or extended following the wrist position because of tension in the extensor or flexor tendons. Patients were instructed to actively flex and extend the wrist under the supervision of the therapist. This 'tenodesis mobilisation' encouraged passive physiological proximal gliding of the flexor tendon and mobilised the repaired site away from the injured site.

Postoperatively days 7 to 10, a 'flex and hold' technique could be added. The therapist first gently flexed all the patient's fingers into the palm and held the patient's hand in a fist. The wrist was then gently extended. Once this position was achieved, the patient was told to hold the grip while the therapist gently let go. This manoeuvre encouraged active contraction of the flexors with minimal resistance.

Patients were usually discharged on postoperative day 5 after having learned the mobilisation techniques and been advised of any necessary precautions to take including avoidance of rigorous exertion and dependency of the hand. Patients were requested to return for daily physiotherapy for 2 weeks. In week 4, the dorsal splint was changed to a neutral wrist splint and progressive, resisted mobilisation was added. Electrical stimulation to the flexor muscles was used cautiously in selected cases. Electrical stimulation should generally not be performed until the repaired tendons have substantially healed (after 6 weeks). It may be used with caution with a slow gradation of stimulation in patients with significant stiffness starting from postoperative week 4. After week 6,

resistive mobilisation aimed at building muscle strength was commenced and passive stretching or splinting was applied if there was flexion contracture or stiffness.

Assessment

All patients were assessed using the total active motion (TAM) scoring system of the American Society for Surgery of the Hand (Table 2). Assessments were carried out at 3, 6, 9, and 12 weeks postoperatively and a final assessment performed after a minimum of 6 months. The power grip and pinch grip were also measured at the same time. The mean TAM measurements and grip strength at each interval were compared using the *t* test. Comparisons with the final assessment were made using the Wilcoxon ranked test with significance set at $p < 0.05$.

RESULTS

Good to excellent results were achieved in 71% of zone-2 repairs and 77% of repairs at other zones ($p < 0.05$) [Table 3]. Progress of recovery of range of motion over time is shown in Figure 2. Repairs at other zones achieved a better range of motion and recovered sooner

Table 2
Total active motion (TAM) scores of the American Society for Surgery of the Hand*

Grade	TAM score
Excellent	100% normal
Good	75–99% normal
Fair	50–74% normal
Poor	<50% normal

* Total active motion = total active flexion (MCP+PIP+DIP) – total extension deficit (MCP+PIP+DIP). MCP denotes metacarpophalangeal joint, PIP proximal interphalangeal joint, and DIP distal interphalangeal joint

Table 3
Final functional results according to total active motion (TAM) score of the American Society for Surgery of the Hand

TAM grade	Zone 2 (n=24)	Other zones (n=22)
Excellent	29%	27%
Good	42%	50%
Fair	25%*	23% [‡]
Poor	4% [†]	0%

* Including one case of rupture and direct repair

† Representing one case of rupture and repair with graft

‡ Including one case of ruptured tenolysis repaired with graft

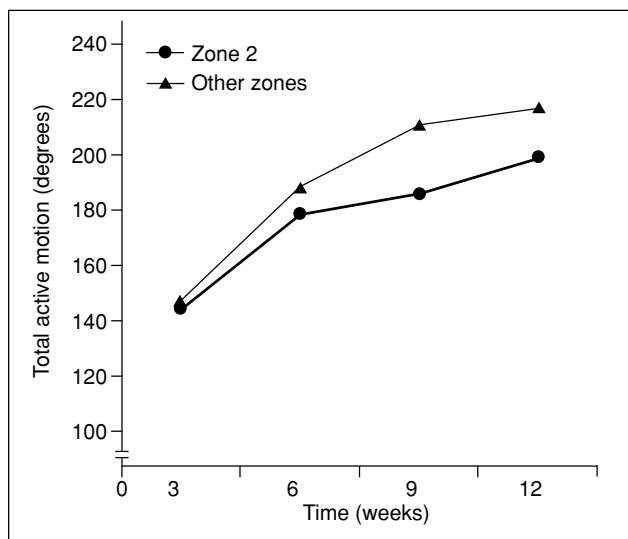


Figure 2 Mean score of total active motion at different intervals for zone 2 and other-zone injuries.

than repairs at zone 2. At week 9, injuries at other zones had a mean of 14% better TAM than zone-2 injuries ($p=0.05$). The final power and pinch grips were similar between the 2 groups ($p=0.82$). The strength of the injured hand was 95% that of the uninjured contralateral side.

Two of the 3 ruptures occurred in zone 2 and one in zone 3. In one case of zone-2 rupture, the tendon injury was missed for about 6 weeks. Direct repair was carried out but a rupture occurred 8 days later. The rupture was repaired again and the active mobilisation programme recommenced. The final result was fair. In another case of zone-2 rupture, initial repair was performed at another hospital, but the patient resumed our active mobilisation programme. The repair ruptured at day 10 and was re-repaired with a tendon graft, active mobilisation was continued afterwards. The final result was poor. The zone-3 rupture occurred after tenolysis at 3 months. The rupture was repaired with a graft and active mobilisation recommenced with a fair outcome. There were no wound complications or infections in any of the patients.

DISCUSSION

Early mobilisation is widely accepted as the most important element of rehabilitation in flexor tendon injuries. Remarkable clinical results are usually obtained with the Kleinert's type of dynamic traction and active extension-passive flexion mobilisation. Nonetheless, poor differential gliding between the superficialis and profundus tendons, in particular in

zone 2, may eventually lead to adhesion formation that compromises the functional result. Some studies have shown that this lack of differential gliding cannot be overcome by passive mobilisation alone,^{9,17} probably due to buckling up of the tendons inside the flexor sheath,¹⁸ or possibly as a result of post-injury oedema and exudative fluid reactions.

Maximum extension of the interphalangeal joints should be achieved to promote passive gliding of the flexor tendons.^{9,17,19-21} Carefully performed, this can give rise to good clinical results although there is a risk of rupturing the repair.^{22,23} Wrist mobilisation is another factor that has been explored to increase tendon gliding.^{9,24} In a recent animal study, mobilising the wrist in gentle flexion and extension significantly improved the final gliding function of the repaired tendon.²⁴ This kind of 'tenodesis mobilisation' has been incorporated in our rehabilitation programme. By flexing the wrist, tension in the extensor tendons brings the fingers into extension. By reversing the wrist into extension, tension in the flexor tendons flexes the fingers. Wrist flexion and extension can be carried out actively if the patient is relaxed and cooperative. If not, it can be gently carried out by the therapist.²⁵ This type of mobilisation helps reduce hand swelling and joint stiffness as well as promoting proximal gliding of the flexor tendons.

Active flexion of the finger definitely contributes to differential gliding between the flexor tendons. Furthermore, active muscle contraction promotes recovery of muscle tone and strength. The loading that is applied to the repaired tendon during active finger flexion improves the subsequent tensile strength after healing.³ The concept of active mobilisation immediately after flexor tendon repair has been tried by various authors: the early clinical results were very impressive and subsequently confirmed by other prospective and comparative studies.¹⁰⁻¹⁶ A mean of 70% to 80% of patients achieved good to excellent results. A long-term review showed that after 10 years, 75% of patients had good to excellent results with a good grip strength in 94%, and 12.8% of patients improved from good to excellent grade.²⁶ Our result matched these findings: overall, 75% of patients had a good to excellent result, with 71% for zone 2 and 77% for other zones ($p<0.05$). We also demonstrated the difference in recovery rate between injuries in zone 2 and other zones. Zone-2 injuries are notorious for their less satisfactory result. They took longer time than other-zone injuries to achieve the same result. Progressive improvement in flexion range and grip strength may be expected for some flexor tendon injuries for up to one year after repair.^{26,27} Repair of zone-2 injuries will eventually achieve

satisfactory results but a longer recovery time should be expected.

Active mobilisation for flexor tendon injury will not be successful if the repair is too weak. Most previous reports and our series used the modified Kessler's repair technique, with the rupture rate ranging from 4.3% to 9.4% (6.5% in our series).^{10,12,14,28} The rupture rate can be significantly reduced when a stronger repair is used.^{11,19,29-31} Some unsatisfactory results are caused by subclinical dehiscence, a gradual stretching and attenuation of the repair that results in a gradual loss of flexion of the injured finger. It is difficult to differentiate this condition from adhesion formation, and the true incidence is unknown. The modified Kessler's repair is only a 2-strand repair, and biomechanical studies have shown that it is probably not strong enough to allow even gentle active flexion of the finger when used alone. A much stronger repair can be provided by one of the 6-strand techniques, that are more technically demanding and may cause more tissue trauma and ischaemic damage.^{29,30,32} It has yet to be shown clinically whether these new techniques significantly improve clinical results. Early clinical results using looped and multi-strand repairs have produced only 69% and 76% good to excellent results in zone-2 injuries.^{11,31} This requires further improvement and exploration.

Inadvertent or unconscious strong gripping of the injured finger, for example, some 'acts of stupidity'³³ or actions performed during sleep, is another frequent cause of rupture. In our programme, patients use a resting platform splint to immobilise the fingers in extension during sleep. The platform splint is removed

during waking hours to allow mobilisation of the fingers.

Cost-benefit is an important factor in the organisation of rehabilitation services. Active mobilisation for flexor tendon injury requires a lot of individual attention from the therapist during the initial 3 weeks. Nonetheless, less splint adjustment or changes may be required than when using the conventional Kleinert's splint that often requires pulley adjustment or change of elastic band. Patient satisfaction is another important factor. Some patients experience pain and stiffness of the finger joints with conventional splinting. Conversely, some patients with the active mobilisation splint have a sense of 'insecurity' and nervous spasm when the fingers are unsupported. These are important issues that should be addressed by a prospective randomised study to compare the 2 rehabilitation programmes.

CONCLUSION

Protected active mobilisation for acute flexor tendon repair is a safe procedure and achieves results comparable with conventional rehabilitation methods. Zone-2 injuries have a delayed recovery compared with injuries to other zones, with slightly inferior overall results. Further improvements in the method and strength of tendon repair are necessary, and a prospective randomised study is required to compare the clinical outcomes, patient satisfaction, and cost-effectiveness of the 2 rehabilitation programmes.

REFERENCES

1. Gelberman RH, Vande Berg JS, Lundborg GN, Akeson WH. Flexor tendon healing and restoration of the gliding surface. An ultrastructural study in dogs. *J Bone Joint Surg Am* 1983;65:70-80.
2. MacMillan M, Sheppard JE, Dell PC. An experimental flexor tendon repair in zone II that allows immediate postoperative mobilization. *J Hand Surg Am* 1987;12:582-9.
3. Hitchcock TF, Light TR, Bunch WH, Knight GW, Sartori MJ, Patwardhan AG, et al. The effect of immediate constrained digital motion on the strength of flexor tendon repairs in chickens. *J Hand Surg Am* 1987;12:590-5.
4. Matthews JP. Early mobilisation after flexor tendon repair. *J Hand Surg Br* 1989;14:363-7.
5. Kleinert HE, Kutz JE, Atasoy E, Stormo A. Primary repair of flexor tendons. *Orthop Clin North Am* 1973;4:865-76.
6. Lister GD, Kleinert HE, Kutz JE, Atasoy E. Primary flexor tendon repair followed by immediate controlled mobilization. *J Hand Surg Am* 1977;2:441-51.
7. Chow JA, Thomes LJ, Dovel S, Milnor WH, Seyfer AE, Smith AC. A combined regimen of controlled motion following flexor tendon repair in "no man's land". *Plast Reconstr Surg* 1987;79:447-55.
8. Strickland JW, Glogovac SV. Digital function following flexor tendon repair in Zone II: a comparison of immobilization and controlled passive motion techniques. *J Hand Surg Am* 1980;5:537-43.
9. Hagberg L, Selvik G. Tendon excursion and dehiscence during early controlled mobilization after flexor tendon repair in zone II: an x-ray stereophotogrammetric analysis. *J Hand Surg Am* 1991;16:669-80.
10. Cullen KW, Tolhurst P, Lang D, Page RE. Flexor tendon repair in zone 2 followed by controlled active mobilisation. *J Hand Surg Br* 1989;14:392-5.
11. Savage R, Risitano G. Flexor tendon repair using a "six strand" method of repair and early active mobilisation. *J Hand Surg Br* 1989;14:396-9.

12. Small JO, Brennen MD, Colville J. Early active mobilisation following flexor tendon repair in zone 2. *J Hand Surg Br* 1989; 14:383–91.
13. Bainbridge LC, Robertson C, Gillies D, Elliot D. A comparison of post-operative mobilization of flexor tendon repairs with “passive flexion-active extension” and “controlled active motion” techniques. *J Hand Surg Br* 1994;19:517–21.
14. Baktir A, Turk CY, Kabak S, Sahin V, Kardas Y. Flexor tendon repair in zone 2 followed by early active mobilization. *J Hand Surg Br* 1996;21:624–8.
15. Gerard F, Garbuio P, Obert L, Tropet Y. Immediate active mobilisation after flexor tendon repairs in Verdan’s zones I and II. A prospective study of 20 cases. *Chir Main* 1998;17:127–32.
16. Peck FH, Bucher CA, Watson JS, Roe A. A comparative study of two methods of controlled mobilization of flexor tendon repairs in zone 2. *J Hand Surg Br* 1998;23:41–5.
17. Silfverskiold KL, May EJ, Tornvall AH. Flexor digitorum profundus tendon excursions during controlled motion after flexor tendon repair in zone II: a prospective clinical study. *J Hand Surg Am* 1992;17:122–31.
18. Horii E, Lin GT, Cooney WP, Linscheid RL, An KN. Comparative flexor tendon excursion after passive mobilization: an in vitro study. *J Hand Surg Am* 1992;17:559–66.
19. May EJ, Silfverskiold KL, Sollerman CJ. The correlation between controlled range of motion with dynamic traction and results after flexor tendon repair in zone II. *J Hand Surg Am* 1992;17:1133–9.
20. Silfverskiold KL, May EJ, Oden A. Factors affecting results after flexor tendon repair in zone II: a multivariate prospective analysis. *J Hand Surg Am* 1993;18:654–62.
21. Silfverskiold KL, May EJ, Tornvall AH. Tendon excursions after flexor tendon repair in zone II: results with a new controlled-motion program. *J Hand Surg Am* 1993;18:403–10.
22. Duran RJ, Coleman CR, Nappi JR, Klerekoper LA. Management of flexor tendon lacerations in zone 2 using controlled passive motion postoperatively. In: Hunter JM, Schneider LH, Mackin EJ, Callahan AD, editors. *Rehabilitation of the hand*. 3rd ed. St Louis: CV Mosby; 1990:410–3.
23. Gerbino PG 2nd, Saldana MJ, Westerbeck P, Schacherer TG. Complications experienced in the rehabilitation of zone I flexor tendon injuries with dynamic traction splinting. *J Hand Surg Am* 1991;16:680–6.
24. Zhao C, Amadio PC, Momose T, Couvreur P, Zobitz ME, An KN. Effect of synergistic wrist motion on adhesion formation after repair of partial flexor digitorum profundus tendon lacerations in a canine model in vivo. *J Bone Joint Surg Am* 2002; 84:78–84.
25. Gratton P. Early active mobilization after flexor tendon repairs. *J Hand Ther* 1993;6:285–9.
26. Riaz M, Hill C, Khan K, Small JO. Long term outcome of early active mobilization following flexor tendon repair in zone 2. *J Hand Surg Br* 1999;24:157–60.
27. May EJ, Silfverskiold KL. Rate of recovery after flexor tendon repair in zone II. A prospective longitudinal study of 145 digits. *Scand J Plast Reconstr Surg Hand Surg* 1993;27:89–94.
28. Elliot D, Moiemmen NS, Flemming AF, Harris SB, Foster AJ. The rupture rate of acute flexor tendon repairs mobilized by the controlled active motion regimen. *J Hand Surg Br* 1994;19:607–12.
29. Gill RS, Lim BH, Shatford RA, Toth E, Voor MJ, Tsai TM. A comparative analysis of the six-strand double-loop flexor tendon repair and three other techniques: a human cadaveric study. *J Hand Surg Am* 1999;24:1315–22.
30. Savage R. In vitro studies of a new method of flexor tendon repair. *J Hand Surg Br* 1985;10:135–41.
31. Tang JB, Gu YT, Rice K, Chen F, Pan CZ. Evaluation of four methods of flexor tendon repair for postoperative active mobilization. *Plast Reconstr Surg* 2001;107:742–9.
32. Tang JB, Shi D, Gu YQ, Chen JC, Zhou B. Double and multiple looped suture tendon repair. *J Hand Surg Br* 1994;19:699–703.
33. Harris SB, Harris D, Foster AJ, Elliot D. The aetiology of acute rupture of flexor tendon repairs in zones 1 and 2 of the fingers during early mobilization. *J Hand Surg Br* 1999;24:275–80.