Journal of Orthopaedic Surgery 2006;14(2):222-4

Thorn prick osteomyelitis of the foot in barefoot walkers: a report of four cases

S Vidyadhara, SK Rao
Department of Orthopaedics, Kasturba Medical College, Manipal, Karnataka, India

ABSTRACT

Walking barefoot is common in developing countries and the feet are therefore exposed to a variety of trivial injuries, some of which lead to cellulitis or abscess formation. If left untreated or improperly managed, osteomyelitis or septic arthritis, usually involving the heel or metatarsals, may follow. In countries with limited resources, the emphasis should be on clinical assessment for diagnosis, and good surgical technique for treatment. We report 4 patients with thorn prick osteomyelitis of the foot due to walking barefoot. All were treated with thorn removal, surgical debridement, and oral ofloxacin. Surgical removal of the thorn is the key to successful treatment and to avoiding recurrent infection.

Key words: *curettage; foot; ofloxacin; osteomyelitis*

INTRODUCTION

Approximately 60% of the one billion population of India reside in rural areas and most walk barefoot to collect firewood, fetch water, clear bush, or herd cattle. Many feet are thus exposed to injuries, such as small cuts, bruises, skin breaches, and puncture wounds by thorns. Most injuries are minor and cause only temporary discomfort. Medical consultation is rarely sought; most patients are self-treated or treated by traditional healers.

Deep-seated infections involving bones can occur following trauma to the foot by a thorn. Late presentation is common in countries with limited and less accessible medical services. Immobility or restricted movement of the foot are the main concerns of patients affected, as the ability to walk unimpeded is necessary for the majority to earn a living.

We report 4 cases of thorn prick osteomyelitis of the foot presenting to the Kasturba Medical College Hospital in Manipal, India from 1994 to 2004. All underwent surgical removal of the thorn with good outcomes.

CASE SERIES

Case 1

In April 1994, a 24-year-old man presented with a history of pain and swelling of the left heel for 8 months. He

Address correspondence and reprint requests to: Dr S Vidyadhara, Assistant Professor, Department of Orthopaedics, Kasturba Medical College, Manipal, 576104, Karnataka, India. E-mail: vidya007@gmail.com

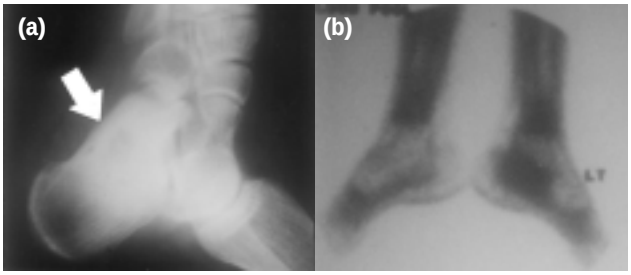

Figure 1 **(a)** Lateral radiograph of the calcaneus showing a lytic lesion surrounded by sclerotic bone (arrow); and **(b)** technetium bone scan showing increased uptake in the left heel.

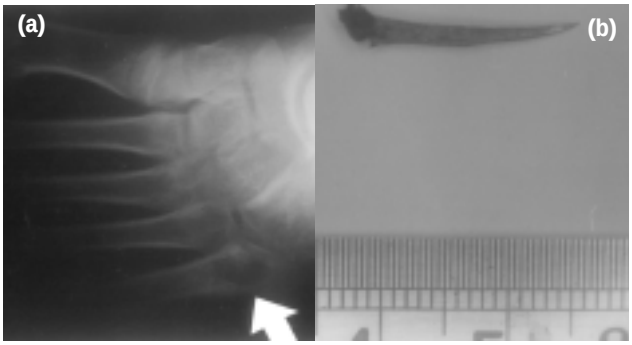

Figure 2 **(a)** Radiograph showing a lytic lesion in the base of the fifth metatarsal and **(b)** the removed thorn.

was pricked by a thorn while walking barefoot in the forest. On presentation, the patient had a history of episodes of fever, walked with a limp and had discharging sinuses over the heel. He reported irregularly taking medicines supplied by rural paramedical personnel. Radiography revealed a lytic lesion of the calcaneus (Fig. 1a). A technetium bone scan showed an area of increased uptake and confirmed the diagnosis of osteoid osteoma of the calcaneus (Fig. 1b). Surgical exploration showed a thorn embedded inside the calcaneus and surrounded by granulation tissue. The thorn was removed and the cavity wall was curetted with a high-speed bur. The wound was closed after drainage. The patient was prescribed 3 weeks of oral ofloxacin, although a culture of the tissue did not grow any microorganisms. A biopsy showed evidence of chronic infection of the granulation tissue. The patient recovered well, with minimal stiffness of the subtalar joint at 2-year follow-up.

Case 2

In August 2000, a 42-year-old woman complained of pain in the foot and swelling of the fifth metatarsal base for 4 months after being pricked by a thorn. This had caused her to limp and she had taken a course of oral antibiotics from her family physician. Radiography revealed an osteolytic lesion in the base of the fifth metatarsal, which was confirmed on computed tomography. Surgical exploration revealed a 6-mm long thorn inside the lytic lesion. Removal of the thorn and thorough curettage of the abscess wall was performed. Cultures grew *Pseudomonas aeruginosa* sensitive to ofloxacillin. After 3 weeks of oral ofloxacin treatment, the patient was pain free and able to walk comfortably. She was asymptomatic at 4-year follow-up.

Case 3

In April 1998, an 18-year-old man presented with a discharging sinus over the outer aspect of the mid-foot after being pricked by a thorn 6 months previously. He had undergone incision and drainage by a traditional healer and had taken a course of oral antibiotics 2 months previously, but the sinus had failed to heal. Radiographs showed a lytic lesion in the base of the fifth metatarsal (Fig. 2a). Surgical exploration revealed a cavity in the fifth metatarsal base, with pale granulation tissue, pus, and a 1.5-cm long thorn present (Fig. 2b). Thorn excision and drainage of the pus and granulation tissue were performed, and oral ofloxacillin was administered for 3 weeks. Culture of the pus grew *Staphylococcus aureus* sensitive to ofloxacin. At 2.5-year follow-up, the patient reported satisfaction with the surgery, but occasional, mild, pain-free swelling over the dorsum of the foot.

Case 4

In October 1996, a 14-year-old boy presented with swelling of the right foot for 5 months. He had pricked his right heel on a thorn a year earlier while playing at school. He underwent incision and drainage of the lesion elsewhere, 3 months prior to this presentation. He reported occasional mild aching in the foot. Radiography revealed a suspicious lytic lesion in the cuboid. Surgical exploration yielded pus, pale granulation tissue, and a 0.5-cm long thorn inside a cavity in the cuboid. The cavity was thoroughly curetted using a high-speed bur, as some areas of the wall were sclerotic. Cultures failed to grow *P aeruginosa* or other microorganisms, but pathological examination of the cavity wall and granulation tissue removed at surgery revealed infected granulation tissue. A 3-week

course of oral ofloxacin was prescribed and was sufficient to heal the infection. At 3-year follow-up, the patient was asymptomatic, with no pain or swelling in the foot.

DISCUSSION

Walking barefoot is common practice in India and the feet are therefore exposed to a variety of minor injuries that are often overlooked. In rare instances, a puncture wound or a skin breach may give rise to serious infection of foot structures.[1,2] Puncture wounds of the foot are rarely complicated by osteomyelitis. If a thorn pierces the soft tissue but not the periosteum, osteomyelitis may not occur. The metatarsal bones and the calcaneus are the usual sites for osteomyelitis because of their contiguity.[3] The heel is a common site for haematogenous osteomyelitis.

None of the patients reported here presented in the acute phase of the condition. Some had visited a village dispensary or had been treated by traditional healers.[4] None had any co-morbid conditions, such as diabetes mellitus or other immunosuppressive diseases. Surgery was necessary in all cases. Long-term follow-up is rarely achieved in India, as in other developing countries. Therefore, the cause of the stiff subtalar joint following heel infection seen in the first patient is unknown, as follow-up radiographs were normal in appearance.

All patients responded well to ofloxacin, although not all cultures grew microorganisms; one grew *P aeruginosa* and one grew *S aureus*, both of which were highly sensitive to ofloxacin. Osteomyelitis of the foot following puncture wounds is mostly caused by gram-negative bacteria,[5] with *P aeruginosa* being the most common causative organism.[6–9] Gram-negative bacteria are very sensitive to quinolones. Although 6 to 8 weeks of antibiotic cover is normally recommended in haematogenous osteomyelitis, oral antibiotics were discontinued after 3 weeks because the wounds healed so well after extensive surgical removal of the offending thorn.

To the best of our knowledge, case 4 is only the second reported case of osteomyelitis of the cuboid in the literature.[10] All patients had radiological evidence of osteomyelitis and had a piece of thorn removed from the osteomyelitic bone. This is the first report about removal of the offending thorn from the bones of the foot with osteomyelitis. Although the thorn itself can produce foreign body granulomatous osteitis without causing infection, all patients had either culture- or biopsy-proven infection. The infection was well controlled with ofloxacin, and all patients were able to return to normal activities. Removal of the thorn is the key to successful treatment and avoidance of recurrent infection.

CONCLUSION

In developing countries, thorn prick-induced osteomyelitis of the foot forms part of the differential diagnosis. Removal of the thorn is the key to successful treatment and early recovery. The most common pathogens are gram-negative bacilli, which respond well to ofloxacin.

REFERENCES

1. Fitzgerald RH Jr, Cowan JD. Puncture wounds of the foot. Orthop Clin North Am 1975;6:965–72.
2. Patzakis MJ, Wilkins J, Brien WW, Carter VS. Wound site as a predictor of complications following deep nail punctures to the foot. West J Med 1989;150:545–7.
3. Waldvogel FA. Acute osteomyelitis. In: David S, editor. Orthopedic infection. New York: Springer; 1988:1–8.
4. Mshiu EN, Chhabra SC. Traditional healers and health care delivery in Tanzania. Trop Doct 1982;12:142–3.
5. Miller EH, Semian DW. Gram-negative osteomyelitis following puncture wounds of the foot. J Bone Joint Surg Am 1975;57: 535–7.
6. Brand RA, Black H. Pseudomonas osteomyelitis following puncture wounds in children. J Bone Joint Surg Am 1974;56: 1637–42.
7. Siebert WT, Dewan S, Williams TW Jr. Case report. Pseudomonas puncture wound osteomyelitis in adults. Am J Med Sci 1982;283:83–8.
8. Johanson PH. Pseudomonas infections of the foot following puncture wounds. JAMA 1968;204:262–4.
9. Feigin RD, McAlister WH, Joaquin VH, Middelkamp JN. Osteomyelitis of the calcaneus. Report of eight cases. Am J Dis Child 1970;119:61–5.
10. Lynch MC, Dorgan JC. A case of Pseudomonas aeruginosa osteomyelitis of the tarsal cuboid following a penetrating wound of the foot in childhood. Injury 1983;14:354–6.