

# Fracture of the os trigonum: a case report

O Kose, AN Okan, MO Durakbasa, K Emrem, NC Islam

Haydarpasa Numune Training and Research Hospital, Second Clinic of Orthopaedics and Traumatology, Istanbul, Turkey

---

## ABSTRACT

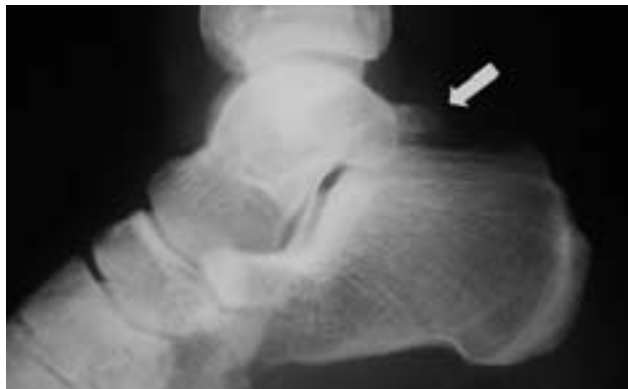The os trigonum is an inconsistently present accessory bone of the foot situated at the posterolateral aspect of the talus. It may be radiographically confused with fractures of the posterior process of the talus. Fracture of the os trigonum per se is extremely rare. Hyperplantarflexion of the ankle is the mechanism of injury in which the os trigonum is compressed between the posterior malleolus of the tibia and the tuber calcaneus. Computed tomography is the choice of imaging modality in cases where fractures of posterior talus structures, including the os trigonum, are suspected. A high index of suspicion is necessary to diagnose a fracture of the os trigonum after a severe plantarflexion injury to the ankle. Conservative treatment is usually successful. We report a case of a fracture of the os trigonum, its clinical features, treatment and significance.

**Key words:** fracture, bone; talus

---

## INTRODUCTION

The os trigonum is an inconsistently present accessory bone of the foot situated at the posterolateral aspect of the talus.<sup>1</sup> It appears between the ages of 8 and 11 years as a secondary centre of ossification and usually fuses with the talus within one year of its appearance.<sup>2,3</sup> When the ossification centre remains separate from the talus it is referred to as the os trigonum, but it is still connected to the lateral tubercle of the posterior process of the talus by a fibrocartilaginous synchondrosis.<sup>2,4</sup> When fusion does occur and a large posterolateral process forms, it is referred to as a 'fused os trigonum', a 'Stieda's process', or a 'trigonal process'.<sup>1,4</sup> The os trigonum is one of the largest and most common accessory ossicles in the ankle and foot region, with an estimated prevalence of 1 to 25% and in some cases can be fragmented or bipartite.<sup>1,3,4</sup> It is usually asymptomatic, presenting as an incidental radiographic finding, but can become symptomatic during or after strenuous physical activities or an acute injury to the ankle. It may be radiographically confused with fractures of the posterior process of the talus.<sup>3,5</sup> Fracture of the os trigonum per se is extremely

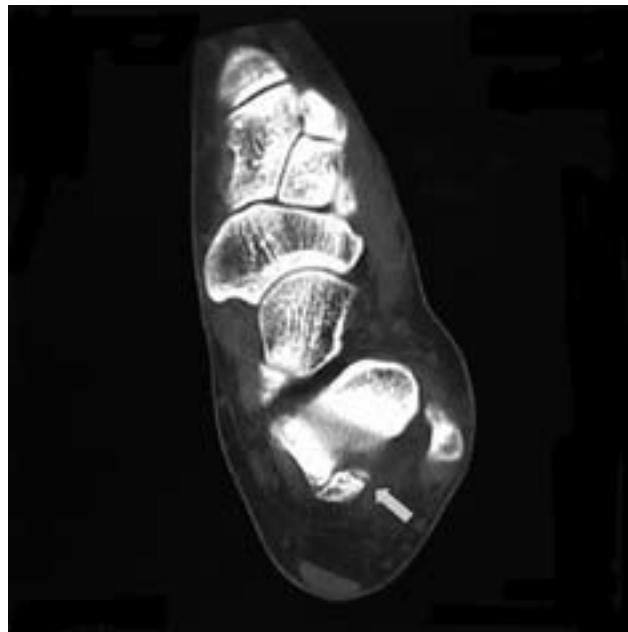


**Figure 1** Lateral radiograph of the left ankle showing an os trigonum (arrow) with no osseous pathology.

rare.<sup>3</sup> Axial computed tomographic (CT) scanning is helpful for differentiating between true talar fractures and an os trigonum. A missed diagnosis can make the pathologies more complex and successful treatment more difficult. We report an unusual case in which a fracture of the os trigonum was observed.

## CASE REPORT

In July 2005, a 32-year-old woman presented to our emergency clinic with an ankle sprain after falling down the stairs. She described experiencing hyperplantarflexion of her left ankle. Her ankle was swollen and she was unable to bear weight. There was great tenderness on palpation on the posterior aspect of her ankle, posterior to the lateral malleolus. The pain was more intense when plantarflexing the ankle. Her medical history revealed no abnormality and her ankle was otherwise normal. Direct radiographs showed the presence of an os trigonum without osseous pathology (Fig. 1). CT axial scans of the ankle showed a fracture of the os trigonum (Fig. 2). It was distinguishable from an os trigonum bipartite by having remarkably sharp edges and discontinuity of the cortical lining, thus a fracture of the os trigonum was diagnosed. A below-knee plaster cast was applied in the neutral position. After 3 weeks of immobilisation, the cast was removed and active ankle motion, together with weight bearing, was encouraged. Six weeks after injury, the patient was well without any symptoms. At 15-month follow-up, the patient remained asymptomatic and had returned to her usual life.



**Figure 2** Axial computed tomographic scan of the left ankle showing the fracture line (arrow) in the os trigonum.

## DISCUSSION

The os trigonum is the most common accessory bone of the foot and is located posterolateral to the talus.<sup>1</sup> Although it is usually asymptomatic, it may be associated with persistent posterior ankle pain known as 'os trigonum syndrome'.<sup>6</sup> It may be misdiagnosed as a fracture of the posterior process of the talus.<sup>1,3,5</sup> Hyperplantarflexion of the ankle is the mechanism of injury, compressing the os trigonum between the posterior malleolus of the tibia and the tuber calcaneus.<sup>7</sup> Clinical symptoms include pain during forced plantarflexion of the ankle, the so-called 'nutcracker sign',<sup>7</sup> which was positive in our case. CT scanning is the imaging choice in cases where posterior talus structure fractures, including an os trigonum fracture, are suspected.<sup>1,3</sup> Hyperplantarflexion ankle injuries may result in posterior ankle compartment fractures, but these are commonly missed and mistreated as simple ankle sprains.<sup>8</sup> Fracture of the os trigonum is a rare entity, thus a high index of suspicion is necessary to diagnose an os trigonum fracture after severe plantarflexion to the ankle. Conservative treatment is usually successful although nonunion has been reported.<sup>2,6</sup>

**REFERENCES**

1. Mellado JM, Ramos A, Salvado E, Camins A, Danus M, Sauri A. Accessory ossicles and sesamoid bones of the ankle and foot: imaging findings, clinical significance and differential diagnosis. *Eur Radiol* 2003;13(Suppl 4):L164–77.
2. Abramowitz Y, Wollstein R, Barzilay Y, London E, Matan Y, Shabat S, et al. Outcome of resection of a symptomatic os trigonum. *J Bone Joint Surg Am* 2003;85:1051–7.
3. Anwar R, Nicholl JE. Non-union of a fractured os trigonum. *Injury* 2005;36:267–70.
4. Bureau NJ, Cardinal E, Hobden R, Aubin B. Posterior ankle impingement syndrome: MR imaging findings in seven patients. *Radiology* 2000;215:497–503.
5. Poh AC, Peh WC. Clinics in diagnostic imaging (95). Os trigonum. *Singapore Med J* 2004;45:140–4.
6. Molly SC, Michael DP. Chronic ankle conditions. In: Banks AS, Downey MS, Martin DE, Miller SJ, editors. *McGlamry's comprehensive textbook of foot and ankle surgery*. Vol II, 3rd ed. Philadelphia: Lippincott Williams and Wilkins; 2001:1097–9.
7. Schubert JM, Adler DC. Talar fractures. In: Banks AS, Downey MS, Martin DE, Miller SJ, editors. *McGlamry's comprehensive textbook of foot and ankle surgery*. Vol I, 3rd ed. Philadelphia: Lippincott Williams and Wilkins; 2001:1871–4.
8. Paulos LE, Johnson CL, Noyes FR. Posterior compartment fractures of the ankle. A commonly missed athletic injury. *Am J Sports Med* 1983;11:439–43.