

# Oldie but goldie: Bristow-Latarjet procedure for anterior shoulder instability

G Matthes, V Horvath, J Seifert, H Ptok, D Stengel, U Schmucker, A Ekkernkamp, P Hinz

Department of Orthopedic and Trauma Surgery, Ernst-Moritz-Arndt-University Greifswald, Greifswald, Germany  
Department of Orthopedic and Trauma Surgery, Unfallkrankenhaus Berlin, Berlin, Germany

---

## ABSTRACT

**Purpose.** To analyse the functional and radiological outcomes of the Bristow-Latarjet procedure in patients with recurrent anterior glenohumeral instability.

**Methods.** Records of 29 patients were reviewed retrospectively. Date of first dislocation, injury mechanism, and number of recurring dislocations before and after surgery were recorded. The overall function and stability of the shoulder was evaluated.

**Results.** 24 (83%) of the glenohumeral instabilities were caused by trauma. The mean number of recurring dislocations was 8 (95% confidence interval [CI], 0–18); one patient had had 40 recurrences. No dislocation ensued postoperatively. The overall functional outcome was good, with a mean Rowe score of 90 points (95% CI, 78–100). Scores of 17 (59%) of the patients were excellent, 7 (24%) were good, 3 (10%) were fair, and 2 (7%) were poor.

**Conclusion.** The Bristow-Latarjet procedure is a good

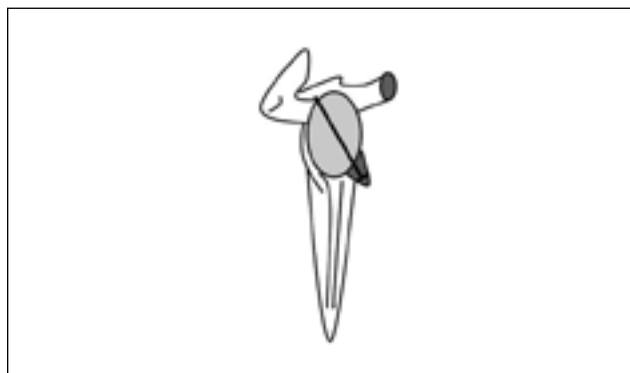
surgical treatment for recurrent anterior-inferior instability of the glenohumeral joint.

**Key words:** shoulder dislocation; treatment outcome

---

## INTRODUCTION

The shoulder is the most mobile joint in humans; its wide range of movement predisposes to a high susceptibility to dislocation. 50% of all joint dislocations involve the shoulder, particularly in young people. The incidence of shoulder dislocation is 12 per 100 000 per year, and if recurring dislocations are counted, it is 17 per 100 000 per year.<sup>1</sup> 95% of shoulder dislocations are anterior-inferior; posterior dislocations account for 3% and other types 2%. Dislocations of the shoulder may be traumatic or non-traumatic. When traumatic, they result from a direct force on the joint or an excessive vectoral force inducing humeral head dislocation. Non-traumatic dislocations may be associated with a dysplastic glenoid.



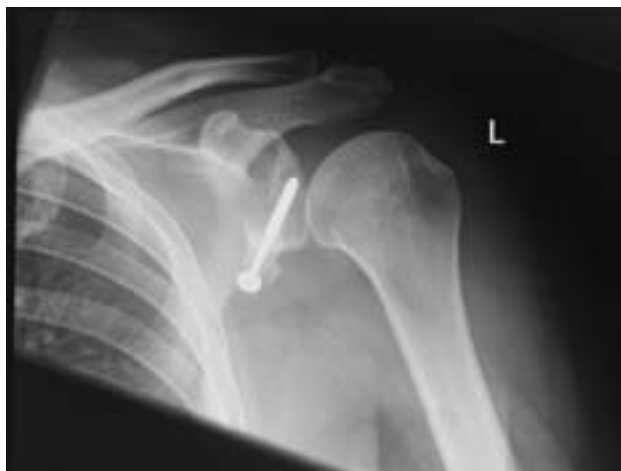**Figure 1** Fixation of the coracoid tip at the anterior-inferior glenoid.

Surgical stabilisation of the glenohumeral joint is indicated when recurrent instability causes discomfort or when pathology is involved. Many surgical methods have been described for the treatment of recurrent anterior shoulder dislocation. Today, the Bristow-Latarjet procedure with detachment of the tip of the coracoid and its transfer to the glenoid is rarely used. We aimed to analyse the functional and radiological outcome of the Bristow-Latarjet procedure in patients with recurrent anterior glenohumeral instability.

## METHODS

The Bristow-Latarjet procedure has been used in our clinic since 1980 for patients with recurrent anterior glenohumeral instability. Available records of patients who underwent this repair between January 1985 and December 2004 inclusive were retrospectively reviewed. Patients with incomplete medical records regarding indication for surgery or functional outcome were excluded. Patient data including date of first dislocation, injury mechanism, number of recurring dislocations before and after surgical repair, time of surgery, follow-up period, and complications were recorded.

The operation entailed a standard axillary incision, thereafter the processus coracoideus was exposed and the musculocutaneous nerve protected. A central drill hole was placed in the coracoid tip using a 3.2-mm drill to facilitate fixation. An osteotomy of the coracoid was performed approximately 1.5 cm proximal to the tip. It is of major importance to keep the insertion of the tendon of the pectoralis at the base of the coracoid process. With the arm in external rotation, the tendon of the subscapularis was vertically



**Figure 2** Postoperative radiograph after the Bristow-Latarjet repair (at 43 months).

transected. We recommend incising the capsule to verify accompanying intra-articular pathologies. The glenoid edge was roughened up 1 cm medial to the glenoid, beneath the glenoid equator. A bicortical drill hole was placed in an anterior-posterior direction. The coracoid tip was transferred and attached by a screw (Fig. 1). With the arm in internal rotation, the tendon of the subscapularis was sutured and the wound closed. The arm was immobilised in adduction and internal rotation for 10 days, and then subjected to a 2-week rehabilitation programme.

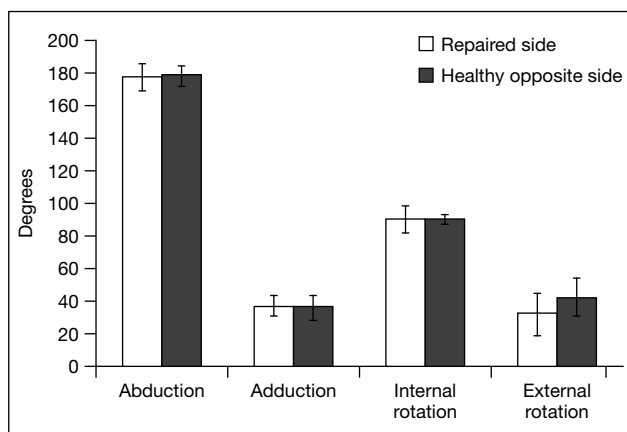
Postoperatively, the range of movement at the glenohumeral joint was measured in all planes. The stability of the shoulder was tested using the apprehension test and Sulcus sign. The overall function and stability of the shoulder was evaluated using the Rowe score.<sup>2,3</sup> Parameters including stability, range of movement, daily function, and pain were evaluated. The final score indicated a poor surgical outcome if it was  $\leq 50$  points, fair if 51 to 74 points, good if 75 to 89 points, and excellent if 90 to 100 points.

A surgeon and a radiologist evaluated postoperative radiographs of the shoulder in antero-posterior, lateral, and true anteroposterior views; fusion of the transplant, position of the screw, and arthrotic degeneration of the glenohumeral joint (classified according to Samilson and Prieto<sup>4</sup>) were assessed (Fig. 2).

Data were collected using an Excel worksheet and analysed using the Statistical Package for Social Sciences (SPSS Inc, Chicago [IL], US). Means were calculated with 95% confidence intervals (CIs).

**Table 1**  
Comparison of studies reporting<sup>5-8</sup> surgical outcomes after the Bristow-Latarjet repair

Studiest	No. of patients	Follow-up (months)	Luxation rate	Subluxation rate	Rowe score			
					Excellent	Good	Fair	Poor
Banas et al., <sup>7</sup> 1993	79	103	4%	-	74%	11%	9%	6%
Singer et al., <sup>6</sup> 1995	14	246	0%	7%	36%	57%	7%	1%
Pap et al., <sup>5</sup> 1997	31	31	3%	-	45%	39%	6%	10%
Hovellius et al. <sup>8</sup> 2004	118	182	4%	9%	71%	15%	11%	4%
Present study, 2007	29	38	0%	3%	59%	24%	10%	7%



**Figure 3** Patients' range of movement after the Bristow-Latarjet repair of shoulder instability.

## RESULTS

The mean follow-up period was 38 (95% CI, 3–74) months. 16 (55%) of the patients were male and 13 (45%) were female. The mean age of the patients at the time of the first shoulder dislocation was 26 (95% CI, 13–39) years. 16 (55%) involved the dominant shoulder. In 24 (83%) the first dislocation was caused by trauma; the remaining 5 (17%) were non-traumatic, one of which ensued during an epileptic seizure and others after a forced external rotation-abduction move of the upper extremity.

The mean number of recurrent dislocations was 8 (95% CI, 0–18) before surgical stabilisation; one patient had had 40 recurrences. No patient had a recurrent dislocation after surgery and their mean postoperative Rowe score was 90 (95% CI, 78–100) points. Scores of 17 (59%) of the patients were excellent, 7 (24%) were good, 3 (10%) were fair, and 2 (7%) were poor (Table 1<sup>5-8</sup>). One (3%) of the latter

patients achieved a Rowe score of 10 points only who had a positive Leffert test in 60°, 90° and 120°, and a positive subluxation sign despite a negative apprehension test finding.

Postoperative range of movement of the repaired glenohumeral joints was good. There was a slight decrease in mean external rotation in the repaired joints compared to the opposite joints (32° [95% CI, 19°–45°] vs 43° [95% CI, 32°–53°]; Fig. 3). However, the difference was not clinically relevant and did not impair activities of daily living.

One (3%) of the patients developed an aseptic necrosis of the transplant with a cutaneous fistula within 8 months of surgery. In the second surgical intervention, the sequestrum was removed and the transferred tendons were left in the scar tissue. The glenohumeral joint remained stable (with a Rowe score of 70) and a further surgical stabilisation was not carried out.

At the follow-up examination, 10 (34%) of the 29 patients had had the screw removed already. Screw loosening was detected in 5 (26%) of the remaining 19 patients. Removal of the screw after bony fusion is recommended. Radiography revealed bony fusion of the transplant in 22 (76%) of the patients, partial dislocation of the transplant in 4 (14%), and no bony fusion in 3 (10%) [Table 2].

## DISCUSSION

Open surgeries have been traditionally used for treatment of anterior glenohumeral instability. In 1994, among 880 German clinics, the most frequently performed surgical procedure for glenohumeral instability was Bankart's procedure (30%), followed by the Eden-Hybinette procedure (29%), the Lange procedure (16%), and the Putti-Platt method (14%).<sup>9</sup> A follow-up in 1997 revealed very similar results.<sup>10</sup>

The Bristow-Latarjet procedure was introduced

**Table 2**  
**Radiographic outcomes of the 29 patients**

Samilson and Prieto grade <sup>3</sup>				Transplant outcome			Screw loosening*	Hill-Sachs lesion
I	II	III	IV	Bony fusion	Dislocation	Nonunion		
3 (10%)	0	0	0	22 (76%)	4 (14%)	3 (10%)	5 (26%)	3 (10%)

\* 10 patients had their screws already removed

by Helfet in 1958.<sup>11</sup> Compared to other surgical procedures for anterior shoulder instability, it confers a remarkable change of the (peri) articular anatomy and its complications necessitate difficult and hazardous revision. The coracoid transfer does not deal with the primary pathology of either traumatic or non-traumatic glenohumeral instability. Therefore, many surgeons rejected this procedure. Nonetheless, the major aim of surgical repair of shoulder instability is prevention of recurrent dislocations. Our patients had no recurrent dislocations after the Bristow-Latarjet repair, consistent with other studies.<sup>5-8</sup> Outcomes of the Bristow-Latarjet procedure are comparable to other open surgical techniques.<sup>12-16</sup> Our patients had good postoperative range of shoulder movement, except for a slight decrease in external rotation, which did not impair activities of daily living. All patients could perform their jobs and sports normally. Despite several instances of screw loosening, patient satisfaction was high and no neurovascular irritation was encountered. Severe complications after screw loosening are sporadic.<sup>11,17-19</sup> Transplant fixation by degradable materials is still under development.<sup>20,21</sup>

Arthroscopic techniques are increasingly popular for treatment of shoulder instability.<sup>22-24</sup> In 2005, a meta-analysis comparing the outcome of open and arthroscopic techniques found a more favourable outcome following open procedures in terms of recurrence and return to activity.<sup>25</sup> Compared to open procedures, the Mantel-Heanzel pooled odds ratio for recurrent instability after arthroscopic repair was 2.04 (95% CI, 1.27-3.29), and it was 2.85 (95% CI, 1.08-3.65) for return to activity, both of which favour open procedures.

## CONCLUSION

The Bristow-Latarjet procedure may be a superior open surgical treatment for recurrent anterior glenohumeral instability, so long as the surgeon is familiar with the technique. Although it is a non-anatomical repair, it provides desirable functional results. Radiological findings (e.g. bony nonunion, screw loosening) do not always correlate with the functional outcome and patient satisfaction.

## REFERENCES

1. Thielemann FW, Holz U. Differential diagnosis of shoulder dislocation with special reference to posterior dislocation [in German]. *Aktuelle Traumatol* 1989;19:274-80.
2. Rowe CR. Instabilities of the glenohumeral joint. *Bull Hosp Joint Dis* 1978;39:180-6.
3. Rowe CR, Zarins B. Recurrent transient subluxation of the shoulder. *J Bone Joint Surg Am* 1981;63:863-72.
4. Samilson RL, Prieto V. Dislocation arthropathy of the shoulder. *J Bone Joint Surg Am* 1983;65:456-60.
5. Pap G, Machner A, Merk H. Treatment of recurrent traumatic shoulder dislocations with coracoid transfer—Latarjet-Bristow operation [in German]. *Zentralbl Chir* 1997;122:321-6.
6. Singer GC, Kirkland PM, Emery RJ. Coracoid transposition for recurrent anterior instability of the shoulder. A 20-year follow-up study. *J Bone Joint Surg Br* 1995;77:73-6.
7. Banas MP, Dalldorf PG, Sebastianelli WJ, DeHaven KE. Long-term follow-up of the modified Bristow procedure. *Am J Sports Med* 1993;21:666-71.
8. Hovelius L, Sandstrom B, Sundgren K, Saebo M. One hundred eighteen Bristow-Latarjet repairs for recurrent anterior dislocation of the shoulder prospectively followed for fifteen years: study I—clinical results. *J Shoulder Elbow Surg* 2004;13:509-16.
9. Jerosch J, Drescher H, Steinbeck J, Lewejohann B. Current concepts in treatment of the unstable shoulder. Results of a countrywide survey [in German]. *Unfallchirurg* 1994;97:64-8.
10. Jerosch J. Arthroscopic therapy of the unstable shoulder joint—acceptance and critical considerations [in German]. *Z*

- Orthop Ihre Grenzgeb 1997;135:79–83.
11. Helfet AJ. Coracoid transplantation for recurring dislocation of the shoulder. *J Bone Joint Surg Br* 1958;40:198–202.
  12. Toolanen G, Kjellgren A, Olsson H, Hogstrom B. The Alvik glenoplasty for the unstable shoulder. Modification of the Eden-Hybinette operation in 66 cases. *Acta Orthop Scand* 1990;61:111–5.
  13. Bigliani LU, Kurzweil PR, Schwartzbach CC, Wolfe IN, Flatow EL. Inferior capsular shift procedure for anterior-inferior shoulder instability in athletes. *Am J Sports Med* 1994;22:578–84.
  14. Gebhard F, Draeger M, Steinmann R, Hoellen I, Hartel W. Functional outcome of Eden-Hybinette-Lange operation in post-traumatic recurrent shoulder dislocation [in German]. *Unfallchirurg* 1997;100:770–5.
  15. Jorgensen U, Svend-Hansen H, Bak K, Pedersen I. Recurrent post-traumatic anterior shoulder dislocation—open versus arthroscopic repair. *Knee Surg Sports Traumatol Arthrosc* 1999;7:118–24.
  16. Guanche CA, Quick DC, Sodergren KM, Buss DD. Arthroscopic versus open reconstruction of the shoulder in patients with isolated Bankart lesions. *Am J Sports Med* 1996;24:144–8.
  17. Cappello T, Nuber GW, Nolan KD, McCarthy WJ. Acute ischemia of the upper limb fifteen years after anterior dislocation of the glenohumeral joint and a modified Bristow procedure. A case report. *J Bone Joint Surg Am* 1996;78:1578–82.
  18. Artz T, Huffer JM. A major complication of the modified Bristow procedure for recurrent dislocation of the shoulder. A case report. *J Bone Joint Surg Am* 1972;54:1293–6.
  19. Iftikhar TB, Kaminski RS, Silva I Jr. Neurovascular complications of the modified Bristow procedure. A case report. *J Bone Joint Surg Am* 1984;66:951–2.
  20. Kartus J, Ejerhed L, Funck E, Kohler K, Sernert N, Karlsson J. Arthroscopic and open shoulder stabilization using absorbable implants. A clinical and radiographic comparison of two methods. *Knee Surg Sports Traumatol Arthrosc* 1998;6:181–8.
  21. Pihlajamaki H, Bostman O, Rokkanen P. A biodegradable expansion plug for fixation of the coracoid bone block in the Bristow-Latarjet operation. *Int Orthop* 1994;18:66–71.
  22. Coughlin L, Rubinovitch M, Johansson J, White B, Greenspoon J. Arthroscopic staple capsulorrhaphy for anterior shoulder instability. *Am J Sports Med* 1992;20:253–6.
  23. Fealy S, Drakos MC, Allen AA, Warren RF. Arthroscopic bankart repair: experience with an absorbable, transfixing implant. *Clin Orthop Relat Res* 2001;390:31–41.
  24. Walch G, Boileau P, Levigne C, Mandrino A, Neyret P, Donell S. Arthroscopic stabilization for recurrent anterior shoulder dislocation: results of 59 cases. *Arthroscopy* 1995;11:173–9.
  25. Mohtadi NG, Bitar IJ, Sasyniuk TM, Hollinshead RM, Harper WP. Arthroscopic versus open repair for traumatic anterior shoulder instability: a meta-analysis. *Arthroscopy* 2005;21:652–8.