

# Congenital pseudarthrosis of the clavicle: a case report

TA Beslikas, DJ Dadoukis, IP Gigis, SP Nenopoulos, JE Christoforides  
Second Orthopaedic Department, Aristotle University of Thessaloniki, Greece

---

## ABSTRACT

Congenital pseudarthrosis of the clavicle is a rare entity of unknown aetiology. Its pathogenesis is related to the embryology of the clavicle. We present a 6-year-old girl with congenital pseudarthrosis of the right clavicle. A prominence was noticed at birth between the middle and distal ends of the clavicle that increased in size when the right shoulder was actively mobilised. Radiographic examination revealed a hypertrophic pseudarthrosis of the clavicle. The pseudarthrosis was resected and the clavicular segments were fixed with an external fixator for 2 months until union. Clinical results were excellent at the 7-year follow-up: the right shoulder was pain-free and the appearance satisfactory. Surgical treatment of congenital pseudarthrosis of the clavicle in children using an external fixator provides a better cosmetic outcome with smaller postoperative scars and avoids a second surgical procedure to remove the implants.

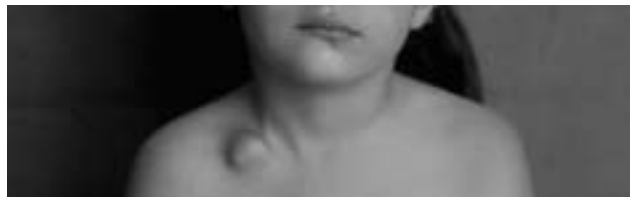**Key words:** clavicle, external fixators, pseudarthrosis, upper extremity deformities, congenital

---


## INTRODUCTION

Congenital pseudarthrosis of the clavicle was first described in 1910.<sup>1</sup> Since then about 200 cases have been reported in the literature. Most cases are unilateral and affect the right clavicle.<sup>2,3</sup> While its aetiology remains unknown,<sup>4</sup> the pathogenesis is related to the embryology of the clavicle.<sup>5,6</sup> The clavicle is a pure membrane bone and is the first osseous mass formed in the embryo. It appears in an 11-mm stage embryo during the fourth week as a mesenchymal bar that lies under the precoracoid area.<sup>5</sup> During the fifth week, the mesenchyme is changed to form pre-cartilage which grows rapidly and becomes 2 ossific plaques in its long axis.<sup>1</sup> During the seventh week, the pre-cartilaginous masses fuse with bony nuclei at the acromial and sternal sides.<sup>1</sup> Most authors believe that the lesion is caused by pressure exerted upon the developing clavicle by the pulsating subclavian artery.<sup>7</sup> The right subclavian artery is normally situated at a higher level, which explains why it is the right clavicle that is almost always affected.

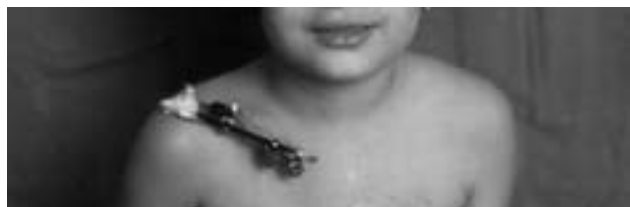Pseudarthrosis of the clavicle on the left side is associated with dextrocardia.<sup>3,6,8</sup> Bilateral involvement is related to an abnormally high subclavian artery on both sides, caused by cervical ribs or high



**Figure 1** A 6-year-old girl with 2.5-cm prominence between the middle and distal third of the right clavicle.



**Figure 2** Pseudarthrosis of the clavicle with enlargement of the acromial and sternal borders.



**Figure 3** Fixation of the clavicle segments with an external fixator.

vertically oriented upper ribs.<sup>4</sup> Other possible causes for the non-union of the 2 ossific nuclei are cervical ribs, vertically disposed and elevated upper ribs or an abnormal intra-uterine position of the embryo.<sup>4</sup> Some cases occur in members of the same family, leading to theories that it may be an inherited disease with an autosomal dominant transmission.<sup>5</sup>

Congenital pseudarthrosis of the clavicle appears as a painless prominence lateral to the middle of the clavicle at birth or in early neonatal life.<sup>1,4,7,9</sup> At the site of the pseudarthrosis, the ends of the clavicular segments are enlarged and there is a degree of motion between them.<sup>4,5</sup> The deformity tends to become more obvious as the child grows and marked mobility is found at the site of the pseudarthrosis.<sup>1,3-5,10</sup> The skin



**Figure 4** Postoperative radiograph showing the external fixation of the clavicle.

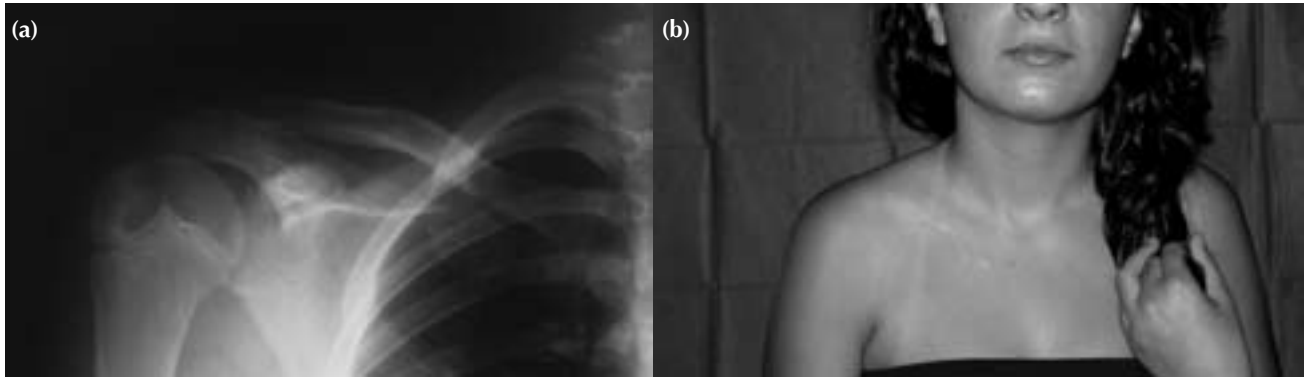
above the prominence becomes thin and atrophic.<sup>1,4</sup> The vertical border of the scapula on the affected side looks asymmetrical and prominent, while the affected shoulder is lower.<sup>1,11</sup> The deformity becomes greater when the patient elevates the arm. Moderate pain may be present around the shoulder girdle and upper arm, while a few patients appear to have functional problems such as weakness of the arm and limited shoulder abduction.<sup>1,4</sup>

We report a 6-year-old girl with congenital pseudarthrosis of the right clavicle causing functional and cosmetic problems. The pseudarthrosis was resected and the clavicular segments were fixed with an external fixator for 2 months until union.

## CASE REPORT

In 1999, a 6-year-old girl presented with a prominence 2.5 cm in size between the middle and distal third of the right clavicle (Fig. 1). The lump was present at birth. There was no history of a difficult delivery or injury. Physical examination revealed a soft mass discontinuous with the clavicular diaphysis. The size of the mass increased with movements of the right shoulder and with abduction and elevation of the right arm, causing mild pain. Clinical findings and plain radiographs of the right shoulder and clavicle confirmed the diagnosis of congenital pseudarthrosis of the clavicle. Radiographs showed an enlargement in the acromial and sternal borders of the clavicle (Fig. 2). Surgical treatment was offered to correct the unacceptable appearance and the functional problems in the right shoulder and arm.

A 3-cm horizontal incision was made above the clavicular prominence, followed by a sharp dissection through the subcutaneous tissues to expose the clavicle. All fibrous and cartilaginous tissue was



**Figure 5** (a) Radiographic and (b) clinical appearance of the right shoulder at 7 years postoperatively.

removed from the site of the pseudarthrosis until healthy osseous tissue was exposed. The clavicular segments were fixed with an external fixator (Fig. 3). The length of the clavicular diaphysis was re-established without bone grafting. Postoperatively a collar and cuff sling was worn for 3 weeks. The external fixator was removed 2 months postoperatively (Fig. 4).

The first signs of healing appeared 4 weeks after surgery and complete union achieved at 2 months. The final radiograph taken 7 years postoperatively was satisfactory (Fig. 5a), even though the right clavicle was 1 cm shorter than the left. The patient had full range of movement of the right shoulder and arm, and was pain-free. The appearance of the shoulder girdle and upper arm was normal (Fig. 5b).

## DISCUSSION

Congenital pseudarthrosis of the clavicle is different from obstetric fracture, post-traumatic non-union, cleidocranial dysostosis, or neurofibromatosis.<sup>1</sup> An obstetric fracture of the clavicle should be suspected when there is a history of a difficult delivery, pseudoparalysis of the arm with no voluntary limb movement and pain on passive movement, or when a massive callus is seen radiographically.<sup>4</sup> Plain radiographs can help differentiate the diagnosis of congenital pseudarthrosis from traumatic non-union because in the latter the bone ends seem attenuated.<sup>4</sup> The feature that distinguishes congenital pseudarthrosis from cleidocranial dysostosis is the absence of other skeletal abnormalities such as skull deformities, small size of the facial bones, scoliosis and deficiencies of the pelvis.<sup>6</sup> Neurofibromatosis is characterised by cafe-au-lait spots on the skin.<sup>3</sup>

When patients are asymptomatic and have no functional disability, some authors do not recommend any treatment.<sup>12-14</sup> Surgical treatment should be considered for symptomatic patients with dysfunction of the arm<sup>12</sup>; when patients are embarrassed by the appearance of the lump<sup>5,15</sup>; and to prevent thoracic outlet syndrome in the future.<sup>10</sup>

The optimal age for surgery is controversial. Some recommend that surgery be done between 3 and 4 years of age.<sup>5,16</sup> Others recommend that the primary excision of the pseudarthrosis be performed during infancy.

Surgical treatment consists of excision of the pseudarthrosis and internal fixation of the bone ends. Tachdjian<sup>4</sup> used a threaded Steinmann pin for fixation, but this is not rigid, leading to possible pin migration. Toledo and MacEwen<sup>17</sup> excised the non-united clavicle and internally fixed it with a Steinmann pin and cancellous bone graft. One of 10 cases was complicated by an acute massive neuropraxia of the brachial plexus postoperatively, successfully treated by immediate removal of the Steinmann pin. Quinlan et al.<sup>16</sup> reconstructed the clavicle by using an iliac crest bone graft and stabilised it with an AO plate and screws. Others have suggested excision of the pseudarthrosis and grafting without using any type of fixation.<sup>1,12,18</sup> Surgical treatment of congenital pseudarthrosis of the clavicle using an external fixator is another possible technique. Since aesthetics are a major concern, the surgery is performed during childhood with an external fixator, yielding better cosmetic results with smaller postoperative scars and avoiding the need for a second surgical procedure to remove the implants. Disadvantages of the external fixator system are the possibility of pin tract infection and the difficulty of taking care of the system until its removal.

**REFERENCES**

1. Owen R. Congenital pseudarthrosis of the clavicle. *J Bone Joint Surg Br* 1970;52:644–52.
2. Cadilhac C, Fenoll B, Peretti A, Padovani JP, Pouliquen JC, Rigault P. Congenital pseudarthrosis of the clavicle: 25 childhood cases [in French]. *Rev Chir Orthop Reparatrice Appar Mot* 2000;86:575–80.
3. Sharrard WJ. Congenital pseudarthrosis of the clavicle. In: *Paediatric orthopaedics and fractures*. Oxford: Blackwell Scientific Publications; 1979:277–80.
4. Tachdjian MO. Pseudarthrosis of the clavicle. In: *Pediatric orthopedics*. Philadelphia: WB Saunders; 1990:168–74.
5. Gibson DA, Carroll N. Congenital pseudarthrosis of the clavicle. *J Bone Joint Surg Br* 1970;52:629–43.
6. Lloyd-Roberts GC, Apley AG, Owen R. Reflections upon the aetiology of congenital pseudarthrosis of the clavicle. With a note on cranio-cleido dysostosis. *J Bone Joint Surg Br* 1975;57:24–9.
7. Hirata S, Miya H, Mizuno K. Congenital pseudarthrosis of the clavicle. Histologic examination for the etiology of the disease. *Clin Orthop Relat Res* 1995;315:242–5.
8. Lloyd-Roberts GC, Fixsen JA. Congenital pseudarthrosis of the clavicle. In: *Orthopaedics in infancy and childhood*. London: Butterworth-Heinemann; 1989:94–5.
9. Lorente Molto FJ, Bonete Lluch DJ, Garrido IM. Congenital pseudarthrosis of the clavicle: a proposal for early surgical treatment. *J Pediatr Orthop* 2001;21:689–93.
10. Beaty JH. Congenital pseudarthrosis of the clavicle. In: *Campbell's operative orthopaedics*. Philadelphia: Mosby; 2003:1132–3.
11. Van Heest A. Pseudarthrosis of the clavicle. In: AR Vaccaro, editor. *Orthopedic knowledge update 8*. AAOS; 2005:698.
12. Grogan DP, Love SM, Guidera KJ, Ogden JA. Operative treatment of congenital pseudarthrosis of the clavicle. *J Pediatr Orthop* 1991;11:176–80.
13. Wall JJ. Congenital pseudarthrosis of the clavicle. *J Bone Joint Surg Am* 1970;52:1003–9.
14. LeGaye J, Noel H, Lokietek W. Congenital pseudarthrosis of the clavicle. A propos of a case report and literature review [in French]. *Acta Orthop Belg* 1991;57:209–12.
15. Schnall SB, King JD, Marrero G. Congenital pseudarthrosis of the clavicle: a review of the literature and surgical results of six cases. *J Pediatr Orthop* 1988;8:316–21.
16. Quinlan WR, Brady PG, Regan BF. Congenital pseudarthrosis of the clavicle. *Acta Orthop Scand* 1980;51:489–92.
17. Toledo LC, MacEwen GD. Severe complication of surgical treatment of congenital pseudarthrosis of the clavicle. *Clin Orthop Relat Res* 1979;139:64–7.
18. Alldred AJ. Congenital pseudarthrosis of the clavicle. *J Bone Joint Surg Br* 1963;45:312–9.