

Modified incision for Brostrom lateral ligament reconstruction of the ankle

Ravindra H Mahajan, Rakesh B Dalal

Department of Orthopaedics, Stepping Hill Hospital, Stockport NHS Foundation Trust, Stockport, United Kingdom

ABSTRACT

Purpose. To describe a modified incision for the Brostrom procedure to correct lateral ankle instability.

Methods. 14 men and 12 women aged 23 to 38 (mean, 27) years with lateral ankle instability underwent the Brostrom procedure with a modified incision to repair both the anterior talofibular and calcaneofibular ligaments, without endangering the sural or superficial peroneal nerves. The incision ran longitudinally over the distal fibula extending 2.5 cm distal to the tip of the lateral malleolus.

Results. There were no instances of wound healing problems, neurological damage, and repair failure. Surgical exposure of all patients was graded as excellent.

Conclusion. The modified incision enables easy repair without endangering the sural and superficial peroneal nerves. Access to the peroneal tendons is allowed if necessary.

Key words: joint instability; lateral ligament, ankle

INTRODUCTION

Most chronic symptomatic lateral ankle instability requires surgical intervention, as this condition damages the anterior talofibular ligament (ATFL) and calcaneofibular ligament (CFL). The ankle is vulnerable to re-injury (especially in dorsiflexion and inversion) unless the CFL is repaired or reinforced along with the ATFL.¹ The split lesion of the peroneus brevis tendon may result from chronic ankle laxity and require a specific surgical technique.² The Brostrom technique—*isometric tightening of the stretched ATFL*—is effective for correction of ankle instability.³⁻⁸ The conventional incision runs in a curvilinear fashion along the anterior border of the lateral malleolus stopping just anterior to the peroneal tendons. However, access to the CFL is insufficient. In the modified Brostrom technique, the lateral portion of the extensor retinaculum is reattached to the distal fibula to reinforce the CFL.⁹ The incision runs from the posterior border of the distal fibula to the base of the fourth metatarsal and curves anteriorly. It is difficult to visualise the CFL and risks injuring the superficial peroneal nerve. We modified the incision for repair of both the ATFL and CFL so as not to endanger the sural and superficial peroneal nerves, while allowing

access to the peroneal tendons if necessary.

MATERIALS AND METHODS

Between 2001 and 2005, 14 men and 12 women aged 23 to 38 (mean, 27) years were diagnosed with symptomatic, lateral ankle instability, confirmed by magnetic resonance imaging and the anterior drawer and varus stress tests under anaesthesia. All 26 patients had the ATFL repaired, whereas 24 had repairs of the CFL, 4 of the inferior extensor retinaculum, and 4 for peroneus brevis tears. Visualisation of the ATFL, CFL and peroneal tendons was categorised according to the pathology and ease of repair.

Popliteal block analgesia was used for peri-operative pain relief. Routine arthroscopy of the ankle was performed to treat osteochondral or impingement lesions.¹⁰ The patient was placed in a lateral position and a thigh tourniquet applied. The bony landmarks of the lateral malleolus, the posterior tuberosity of the calcaneum, and the base of the fifth metatarsal were identified. A linear incision was made over the distal fibula from a point 5 cm proximal to the tip of the lateral malleolus and extended distally for approximately 1.3 cm. The dissection was made through the superficial fascia and underlying fat to identify the capsule running along the anterior border of the lateral malleolus (Fig.). The ATFL (which attaches to the anterior aspect of the lateral malleolus running towards the talus as a thickened part of the capsule) was usually ruptured or stretched (in chronic instability). It was then isolated and divided into proximal and distal flaps, leaving a cuff of tissue attached to the lateral malleolus for precise isometric repair. The distal flap was sutured onto the fibula using suture anchors or drilling holes. The proximal flap was double breasted over the distal flap to augment the repair. The CFL (which runs deep to the peroneal tendons at the posteroinferior margin of the lateral malleolus) was also double breasted in a similar manner if it was stretched or ruptured. The peroneus brevis and longus were then exposed for about 2.5 cm on either side of the lateral malleolus to look for evidence of fraying or tears. Split tears were debrided and repaired. Care was taken to preserve and protect the superficial peroneal and the sural nerves. The strength of the repair was then tested and the wound closed in layers.

Postoperatively, the legs were kept in a below-knee plaster non-weight bearing for 3 weeks. Weight bearing was allowed in a fixed ankle brace at 3 weeks with support. Full weight bearing without brace was started at 6 weeks. Contact sports were resumed after

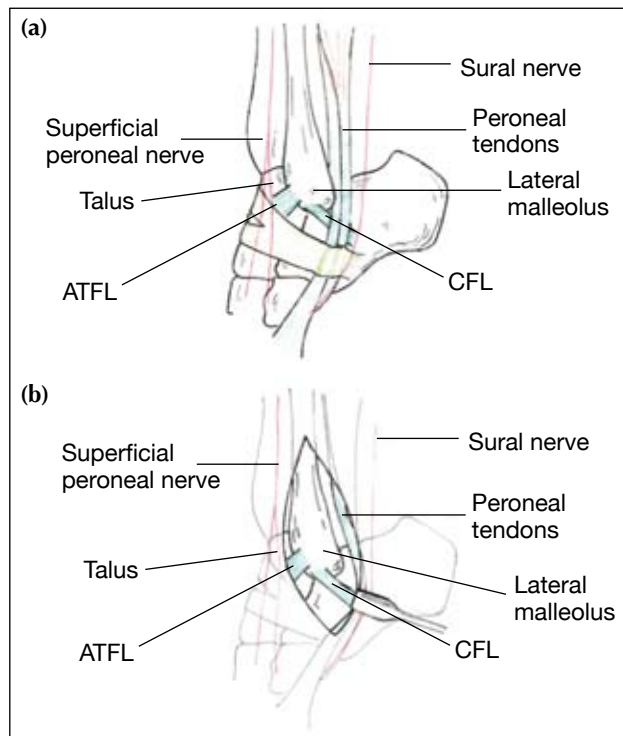


Figure (a) Relation of the cutaneous nerves and the lateral ligament complex. (b) Exposure of the anterior talofibular ligament (ATFL), calcaneofibular ligament (CFL), and peroneal tendons, with all nerves preserved.

3 to 6 months.

RESULTS

Patients were followed up for 6 to 24 months. There were no instances of wound healing problems, neurological damage, or repair failure. In all patients, surgical exposure was graded as excellent.

DISCUSSION

The primary static restraints to an inversion injury of the ankle are the ATFL and CFL.¹¹ The CFL prohibits adduction and acts almost independently in neutral and dorsiflexed positions. In plantar flexion it restricts adduction in conjunction with the ATFL. After sectioning the CFL, the rotation of talocalcaneal joint increases 20% and talocalcaneal adduction increases 61% to 77%.^{12,13}

Anatomic reconstruction restores ligamentous

force more close to normal than do the Checkerin procedures.¹⁴ The Watson-Jones, Evans, and Chrisman-Snook procedures are associated with variable subjective instability.¹⁵⁻¹⁷ The modified Brostrom procedure attains greater mechanical restraint than either the Evans or Chrisman-Snook procedure.^{18,19}

Repair of both the ATFL and CFL achieves better functional results than repair of the ATFL alone,²⁰ particularly in patients with subtalar instability.²¹ The modified Brostrom technique restores the anatomic alignment and static functions of both the ATFL and CFL and thus is the treatment of choice for persistent ankle instability refractory to a functional ankle-rehabilitation protocol.¹¹

The straight incision provides easy access to both the ATFL and CFL, and minimises the risk of injuring

cutaneous nerves in the vicinity, as it runs parallel to both the sural and lateral branches of the superficial peroneal nerve. It also minimises damage to the adjacent host tissue. The peroneal tendons are well visualised and any associated pathology (such as tears secondary to instability) can be addressed. Residual pain after repair can be due to a neglected peroneus brevis tear.² It is therefore important to restore normal function to the peroneal tendons for proprioception and neuromuscular stability of the ankle and hind foot, especially for dancers and athletes. Both the Evans and Chrisman-Snook procedures result in weakness in the affected limb (compared to the contralateral limb).²² Routine arthroscopy of the ankle should be performed before the Brostrom procedure, as about 83% of patients also have intra-articular problems.¹⁰

REFERENCES

- Girard P, Anderson RB, Davis WH, Isear JA, Kiebzak GM. Clinical evaluation of the modified Brostrom-Evans procedure to restore ankle stability. *Foot Ankle Int* 1999;20:246-52.
- Bonnin M, Tavernier T, Bouysset M. Split lesions of the peroneus brevis tendon in chronic ankle laxity. *Am J Sports Med* 1997;25:699-703.
- Brostrom L. Sprained ankles. I. Anatomic lesions in recent sprains. *Acta Chir Scand* 1964;128:483-95.
- Brostrom L. Sprained ankles. III. Clinical observations in recent ligament ruptures. *Acta Chir Scand* 1965;130:560-9.
- Brostrom L. Sprained ankles. V. Treatment and prognosis in recent ligament ruptures. *Acta Chir Scand* 1966;132:537-50.
- Brostrom L. Sprained ankles. VI. Surgical treatment of "chronic" ligament ruptures. *Acta Chir Scand* 1966;132:551-65.
- Brostrom L, Liljedahl SO, Lindvall N. Sprained ankles. II. Arthrographic diagnosis of recent ligament ruptures. *Acta Chir Scand* 1965;129:485-99.
- Brostrom L, Sundelin P. Sprained ankles. IV. Histologic changes in recent and "chronic" ligament ruptures. *Acta Chir Scand* 1966;132:248-53.
- Gould N, Seligson D, Gassman J. Early and late repair of lateral ligament of the ankle. *Foot Ankle* 1980;1:84-9.
- Kibler WB. Arthroscopic findings in ankle ligament reconstruction. *Clin Sports Med* 1996;15:799-804.
- Baumhauer JF, O'Brien T. Surgical considerations in the treatment of ankle instability. *J Athl Train* 2002;37:458-62.
- Kjaersgaard-Andersen P, Wethelund JO, Nielsen S. Lateral talocalcaneal instability following section of the calcaneofibular ligament: a kinesiologic study. *Foot Ankle* 1987;7:355-61.
- Kjaersgaard-Andersen P, Wethelund JO, Helmig P, Soballe K. The stabilizing effect of the ligamentous structures in the sinus and canalis tarsi on movements in the hindfoot. An experimental study. *Am J Sports Med* 1988;16:512-6.
- Krips R, Brandsson S, Swensson C, van Dijk CN, Karlsson J. Anatomical reconstruction and Evans tenodesis of the lateral ligaments of the ankle. Clinical and radiological findings after follow-up for 15 to 30 years. *J Bone Joint Surg Br* 2002;84:232-6.
- Sugimoto K, Takakura Y, Akiyama K, Kamei S, Kitada C, Kumai T. Long-term results of Watson-Jones tenodesis of the ankle. Clinical and radiographic findings after ten to eighteen years of follow-up. *J Bone Joint Surg Am* 1998;80:1587-96.
- Rosenbaum D, Becker HP, Sterk J, Gerngross H, Claes L. Functional evaluation of the 10-year outcome after modified Evans repair for chronic ankle instability. *Foot Ankle Int* 1997;18:765-71.
- Hollis JM, Blasier RD, Flahiff CM, Hofmann OE. Biomechanical comparison of reconstruction techniques in simulated lateral ankle ligament injury. *Am J Sports Med* 1995;23:678-82.
- Burks RT, Morgan J. Anatomy of the lateral ankle ligaments. *Am J Sports Med* 1994;22:72-7.
- Colville MR. Surgical treatment of the unstable ankle. *J Am Acad Orthop Surg* 1998;6:368-77.
- Karlsson J, Bergsten T, Lansinger O, Peterson L. Reconstruction of the lateral ligaments of the ankle for chronic lateral instability. *J Bone Joint Surg Am* 1988;70:581-8.
- Heilman AE, Braly WG, Bishop JO, Noble PC, Tullos HS. An anatomic study of subtalar instability. *Foot Ankle* 1990;10:224-8.
- St Pierre RK, Andrews L, Allman F Jr, Fleming LL. The Cybex II evaluation of lateral ankle ligamentous reconstructions. *Am J Sports Med* 1984;12:52-6.