

# Anatomic variations of neurovascular structures of the ankle in relation to arthroscopic portals: a cadaveric study of Chinese subjects

Siu-Bon Woo,<sup>1</sup> Tak-Man Wong,<sup>1</sup> Wai-Lam Chan,<sup>1</sup> Chi-Hung Yen,<sup>1</sup> Wing-Cheung Wong,<sup>1</sup> Kong-Ling Mak<sup>2</sup>

<sup>1</sup> Department of Orthopaedics and Traumatology, Kwong Wah Hospital, Hong Kong

<sup>2</sup> Department of Pathology, Kwong Wah Hospital, Hong Kong

---

## ABSTRACT

**Purpose.** To investigate anatomic variations of neurovascular structures in the ankle and the safety margin for arthroscopic portals.

**Methods.** 11 left and 12 right ankles from 8 female and 15 male fresh cadavers of Chinese ethnicity aged 53 to 88 (mean, 68) years were used. The ankle was standardised in a plantigrade position, zero-degree inversion, and neutral rotation. Four ankle portals, namely anteromedial (AM), anterolateral (AL), posteromedial (PM) and posterolateral (PL), were identified using 23-gauge needles. Skin and subcutaneous fat were dissected from the underlying fascia to visualise neurovascular structures. Distances were measured from: (1) the AM portal to the saphenous vein and nerve and its branches, (2) the AL portal to branches of the superficial peroneal nerves, of which the lateral one was labelled as the intermediate dorsal cutaneous branch and the medial one as the medial dorsal cutaneous branch, (3) the PM portal to the posterior tibial neurovascular bundles,

and (4) the PL portal to the sural nerve.

**Results.** The distances from (1) the AM portal to branches of the great saphenous vein and nerve, and (2) the AL portal to the intermediate dorsal cutaneous branch of the superficial peroneal nerve were short and may be an anatomic hazard. Variations were significant among the cadavers in terms of distances of the portals to the neurovascular structures.

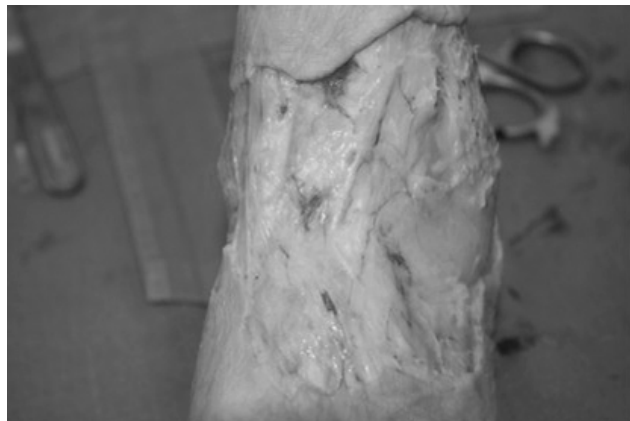
**Conclusion.** In Chinese cadavers, variations of neurovascular structures are significant. Care must be taken to avoid inadvertent injury during ankle arthroscopy.

**Key words:** ankle; arthroscopy; complications

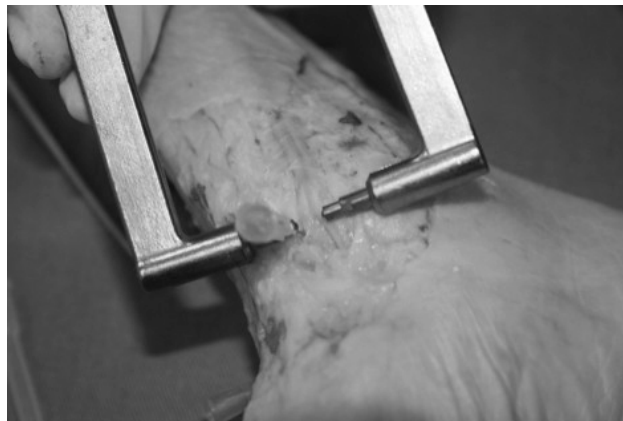
---

## INTRODUCTION

Ankle arthroscopy has been used for treatment of a variety of ankle pathologies (e.g. synovitis, loose bodies, impingement, intra-articular fractures, osteochondral lesions, and arthrodesis). Advances in minimally invasive techniques have hastened recovery of patients and minimised morbidities.



**Figure 1** Skin and subcutaneous fat were dissected from underlying fascia for visualisation of neurovascular structures.



**Figure 2** An analogue thickness gauge with ball tips measurable to 0.05 mm is used for distances <15 mm.

The success of surgery mainly depends on safe establishment of arthroscopic portals in relation to adjacent neurovascular structures, and thus avoid inadvertent injury.<sup>1</sup> We investigated anatomic variations of neurovascular structures of the ankle and the safety margin for arthroscopic portals.

## MATERIALS AND METHODS

Between January 2007 and December 2008, 11 left and 12 right ankles from 8 female and 15 male fresh cadavers of Chinese ethnicity aged 53 to 88 (mean, 68) years with no infectious disease<sup>2</sup> were studied. *Rigor mortis* had not set in and there was no detectable abnormality, impaired passive range of movement, and illness history involving the ankle joints. Informed consent was obtained from the next of kin. All procedures were performed inside a biosafety level-2 suite.<sup>2</sup> Personal protection equipment (such as face shields, protective gloves and impermeable gowns) was used.<sup>3</sup>

The surface landmarks (namely prominences of the medial and lateral malleoli, borders of the Achilles tendon, and the medial border of the tibialis anterior tendon) were identified, with the skin intact. The ankle was standardised in a plantigrade position, zero-degree inversion, and neutral rotation. Four ankle portals, namely anteromedial (AM), anterolateral (AL), posteromedial (PM) and posterolateral (PL), were identified using 23-gauge needles inserted through the joint capsule.<sup>1,4-11</sup> Skin and subcutaneous fat were dissected from the underlying fascia for visualisation of neurovascular structures (Fig. 1).

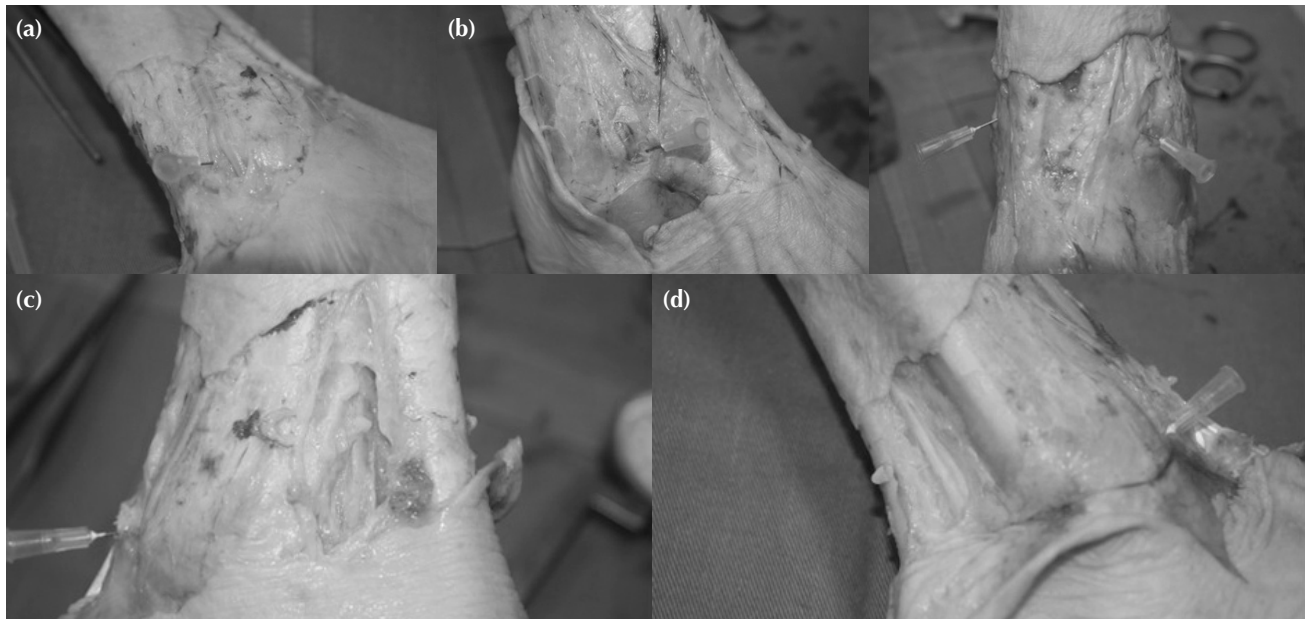
Care was taken to avoid disturbing the fascia and neurovascular structures. The distances of the portals to the corresponding neurovascular structures were measured,<sup>12-15</sup> using a thickness gauge with ball tips measurable to 0.05 mm for distances <15 mm [Fig. 2] or a tape ruler for distances >15 mm. They included (1) the AM portal to the saphenous vein and nerve and its branches, (2) the AL portal to branches of superficial peroneal nerves, of which the lateral one was labelled as the intermediate dorsal cutaneous branch and the medial one as the medial dorsal cutaneous branch, (3) the PM portal to posterior tibial neurovascular bundles, and (4) the PL portal to the sural nerve (Fig. 3). A mean of 3 measurements was recorded to reduce intra-observer error.

## RESULTS

Variations were significant among the cadavers in terms of patient age and distances from the medial to lateral malleoli, the AM portal to the saphenous nerve and vein and their branches, the AM portal to the anterior tibial artery, the AM portal to the deep peroneal nerve, the AL portal to the superficial peroneal nerve, the PL portal to the sural nerve, and the PM portal to posterior tibial neurovascular bundles (Table).

## DISCUSSION

Distances from (1) the AM portal to branches of the great saphenous vein and nerve (mean, 5.4; range,

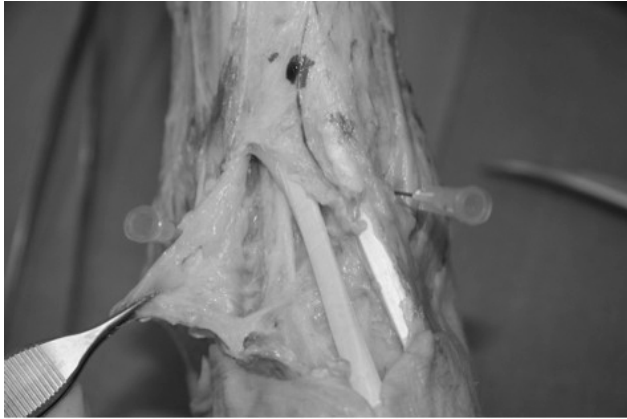

**Figure 3** Measurement of distances from (a) the anteromedial portal to the saphenous vein and nerve and its branches, (b) the anterolateral portal to branches of superficial peroneal nerves, of which the lateral one is labelled as the intermediate dorsal cutaneous branch and the medial one as the medial dorsal cutaneous branch, (c) the posteromedial portal to posterior tibial neurovascular bundles, and (d) the posterolateral portal to the sural nerve.

**Table**  
Distances between arthroscopic portals and corresponding neurovascular structures

Patient no.	Age (years)	Distances between arthroscopic portals and corresponding neurovascular structures* (mm)							
		M-L	AM-Sap NV	AM-Sap Br	AM-ATA	AM-DPN	AL-SPN	PL-Sural	PM-PT NV
1	65	103	20.2	8.4	23.5	20.7	8.5	7.7	7.6
2	58	115	1.1	7.5	24.3	20.6	0.4	7	14
3	76	105	18.0	10	25.1	23.8	0.6	21.8	8
4	55	107	3.5	0.5	25.8	22.0	12.5	10.2	7.5
5	65	104	11.3	13.1	23.8	22.1	0.5	23	9.9
6	88	112	15.6	5.6	25.0	23.8	0.6	20.2	16.3
7	71	102	10.2	2.4	25.1	21.6	5.4	9.3	13.6
8	77	109	8.4	3.2	24.2	20.2	3.8	15.4	20.5
9	55	105	15.6	0.8	24.2	21.7	7.8	8.9	10.0
10	53	118	12.8	9.6	24.9	22.5	5.6	8.6	19.8
11	58	115	1.8	1.2	25.8	23.1	2.8	9.9	17.2
12	53	119	16.2	8.6	23.7	18.9	1.7	13.4	10.2
13	70	110	1.4	6.8	26.4	22.7	0.5	17.2	11.4
14	55	107	12.2	2.7	26.2	24.4	9.8	9.1	10.3
15	76	104	1.6	8.2	23.9	22.0	7.6	8.8	9.7
16	80	118	15.8	7.2	23.6	21.8	8.2	12.5	22.1
17	70	111	13.2	8.8	25.2	23.7	5.1	13.2	19.5
18	77	110	4.7	2.7	26.0	24.0	8.0	7.8	19.0
19	55	109	13.2	0.7	25.6	23.2	0.4	9.9	17.7
20	71	102	2.0	2.4	24.9	21.8	11.7	23.0	5.2
21	74	116	14.5	7.5	24.2	21.6	6.0	15.6	21.2
22	74	114	7.9	2.5	26.1	24.3	14.4	8.1	18.2
23	88	112	13.4	3.1	24.0	22.0	4.3	9.1	16.6
<b>Mean</b>	<b>68</b>	<b>109.9</b>	<b>10.2</b>	<b>5.4</b>	<b>24.8</b>	<b>22.3</b>	<b>5.5</b>	<b>12.6</b>	<b>14.2</b>
<b>(range)</b>	<b>(53–88)</b>	<b>(102–119)</b>	<b>(1.1–20.2)</b>	<b>(0.5–13.1)</b>	<b>(23.5–26.4)</b>	<b>(18.9–24.4)</b>	<b>(0.4–14.4)</b>	<b>(7.0–23.0)</b>	<b>(5.2–22.1)</b>

\* M-L denotes medial-lateral malleoli distance, AM-Sap NV anteromedial portal to saphenous vein and nerve distance, AM-Sap Br anteromedial portal to branch of saphenous vein and nerve distance, AM-ATA anteromedial portal to anterior tibial artery distance, AM-DPN anteromedial portal to deep peroneal nerve distance, AL-SPN anterolateral portal to superficial peroneal nerve distance (intermediate dorsal cutaneous branch), PL-Sural posterolateral portal to sural nerve distance, and PM-PT NV posteromedial portal to posterior tibial neurovascular bundles distance



**Figure 4** Using the medial border of the tibialis anterior tendon as reference point in measurement is subject to variations in ankle positions, especially after dissection of fascia for identification of the anterior tibial artery and deep peroneal nerve.

0.5–13.1 mm), and (2) the AL portal to the intermediate dorsal cutaneous branch of the superficial peroneal nerve (mean, 5.5; range, 0.4–14.4 mm) were short, and thus may be an anatomic hazard. To avoid inadvertent injury to nearby neurovascular structures, (1) the AM portal should be placed >13 mm lateral to the standard portal at the AM corner of the talocrural joint; (2) the AL portal should be placed as close to the fibula as possible, and a straight haemostat should be used to snipe and spread prior to trocar insertion to avoid neuropraxia or vessel injury even if the nerves are in

the way of the portal; (3) the PM and PL portals should be placed next to the border of the Achilles tendon, as the posterior tibial neurovascular bundles and the sural nerve are far from the border of the Achilles tendon. In addition, a larger size arthroscope should be avoided. Transverse skin incisions achieve better cosmesis, and larger incisions minimise collection of subcutaneous fluid.

In our study, the medial border of the tibialis anterior and peroneus tertius tendons were not used as reference points in measurement, because they are not readily identifiable through skin and susceptible to variations in ankle position, especially after dissection of fascia for identification of the anterior tibial artery and deep peroneal nerve (Fig. 4).

There are 5 types of superficial peroneal nerve divisions.<sup>16</sup> In our subjects, only intermediate and medial dorsal cutaneous nerves were identified at the ankle joint level; other bifurcations were observed distally but not related to the ankle portals.

Our results cannot be generalised, because of the limited number of specimens and considerable variation in ankle size. The body mass index should be taken into account in future studies.

#### ACKNOWLEDGEMENTS

We thank Dr HB Leung for secretarial support and Ms Kian Chong for statistical analysis. We are grateful for the research grant from the Tung Wah Group of Hospitals, and family members of the deceased.

#### REFERENCES

1. Ferkel RD, Small HN, Gittins JE. Complications in foot and ankle arthroscopy. *Clin Orthop Relat Res* 2001;391:89–104.
2. Precautions for handling and disposal of dead bodies. Department of Health, Hospital Authority, Food and Environmental Hygiene Department. 4th ed. January 2002.
3. Biosafety in microbiological and biomedical laboratories. U.S. Department of Health and Human Services, Centers for Disease Control and Prevention, National Institutes of Health, 4th ed. May 1999.
4. Golano P, Vega J, Perez-Carro L, Gotzens V. Ankle anatomy for the arthroscopist. Part I: The portals. *Foot Ankle Clin* 2006;11:253–73.
5. Niek van Dijk C, van Bergen CJ. Advancements in ankle arthroscopy. *J Am Acad Orthop Surg* 2008;16:635–46.
6. Carson WG Jr, Andrews JR. Arthroscopy of the ankle. *Clin Sports Med* 1987;6:503–12.
7. Parisien JS, Vangsness T, Feldman R. Diagnostic and operative arthroscopy of the ankle. An experimental approach. *Clin Orthop Relat Res* 1987;224:228–36.
8. Andrews JR, Previte WJ, Carson WG. Arthroscopy of the ankle: technique and normal anatomy. *Foot Ankle* 1985;6:29–33.
9. Plank E. Arthroscopy of the ankle joint [in German]. *Hefte Unfallheilkd* 1978;131:245–51.
10. Basarir K, Esmer AF, Tuccar E, Binnet M, Guclu B. Medial and lateral malleolar arteries in ankle arthroscopy: a cadaver study. *J Foot Ankle Surg* 2007;46:181–4.
11. Sitler DF, Amendola A, Bailey CS, Thain LM, Spouge A. Posterior ankle arthroscopy: an anatomic study. *J Bone Joint Surg Am* 2002;84:763–9.
12. Ucerler H, Ikiz AA, Uygur M. A cadaver study on preserving peroneal nerves during ankle arthroscopy. *Foot Ankle Int* 2007;28:1172–8.
13. Ogut T, Akgun I, Kesmezacar H, Turker T, Uzun I, Demirci S, et al. Navigation for ankle arthroscopy: anatomical study of

- the anterolateral portal with reference to the superficial peroneal nerve. *Surg Radiol Anat* 2004;26:268–74.
14. Saito A, Kikuchi S. Anatomic relations between ankle arthroscopic portal sites and the superficial peroneal and saphenous nerves. *Foot Ankle Int* 1998;19:748–52.
  15. Drizenko A, Demondion X, Luyckx F, Mestdagh H, Cassagnaud X. The communicating branches between the sural and superficial peroneal nerves in the foot: a review of 55 cases. *Surg Radiol Anat* 2004;26:447–52.
  16. Takao M, Uchio Y, Shu N, Ochi M. Anatomic bases of ankle arthroscopy: study of superficial and deep peroneal nerves around anterolateral and antero-central approach. *Surg Radiol Anat* 1998;20:317–20.